

Short Communication / Kısa Bilimsel Çalışma

Conjunctival leiomyosarcoma in a dog

Nihat YUMUŞAK¹, Murat ÇALIŞKAN², Osman KUTSAL³

¹ Harran University, Faculty of Veterinary Medicine, Department of Pathology, Sanliurfa; Ankara University, Faculty of Veterinary Medicine, ²Department of Surgery; ³Department of Pathology, Ankara, Turkey.

Summary: In the case, leiomyosarcoma is described pathomorphologically in conjunctiva of a 5 years old male dog. Macroscopically, the mass were weight of 14 g, 4x4x3 cm in diameter, grayish-white and firm consistency. On cut section, there were generally grayish white color but included haemorrhagic foci in some areas. Histologically, anaplastic muscle cells, were seen ovoid or spindle shape, had architecture of bundles in different way or whorles. The cells were differentiated by staining red in Masson's trichrome method. In addition, haemorrhagic areas were get along with these cells.

Key words: Conjunctiva, dog, leiomyosarcoma.

Bir köpekte konjunktival leiomyosarkom

Özet: Bu olguda, sol gözün alt kapağında şişlik şikayeti bulunan 5 yaşlı, erkek bir köpeğin konjunktivasından alınan biyopsi örneğinde leiomyosarkom olgusu patomorfolojik olarak tanımlandı. Tümöral kitle makroskobik olarak, 14 gr ağırlığında, 4x4x3 cm boyutlarında ve elastik kıvamlıydı. Kesit yüzü ise boz-beyaz renkte ve yer yer küçük kanama alanları mevcuttu. Histolojik olarak ise çeşitli yönlere kollar veren bantlar veya girdaplar yapmış, Masson'un trikrom boyası ile kırmızı renkte boyanan, oval veya uzunca görünüşlü anaplazik kas hücrelerinden oluşan yapılara kanama alanlarının eşlik ettiği görüldü.

Anahtar sözcükler: Köpek, konjunktiva, leiomyosarkom.

Leiomyosarcoma is a slow-developing and localised malignant tumour of smooth muscle (2, 4, 9, 11). This type of tumour is generally located in the digestive tract, liver, kidneys, urinary bladder and uterus. Although leiomyosarcomas occur in dogs of any age or breed, tumours in the spleen and urinary bladder are mostly observed in senile animals (2-4, 11, 12). In dogs, while vascular tumours, melanomas, papillomas and mast cell tumours are common in and around the eyes, mesenchymal tumours are rare in this particular site (5, 6, 8, 10). This case study provides the pathomorphological description of a leiomyosarcoma located in the conjunctiva of a dog.

The biopsy material taken from the conjunctiva of a 5-year-old male dog suffering from a swelling in the left eye, constituted the material of this case study (Figure 1). Macroscopic examination demonstrated that the tumour was 14 g in weight, 4x4x3 cm in size, and of elastic consistency. The cross-section of the mass was greyish white in colour, had a lobular appearance and presented with patches of small haemorrhages. The tissue sample was fixed in 10% buffered formaldehyde solution. After passed through graded alcohol and xylol series, the tissue

was embedded in paraffin. Five-micron-thick sections were cut from the paraffin blocks and subjected to Masson's trichrome staining for muscle tissue identification and also to haematoxylin-eosin staining (HxE). The stained sections were examined by light microscopy. Histologically, anaplastic muscle cells, were seen ovoid or spindle shape, had architecture of bundles in different way or whorles (Figure 2). The cells were differentiated by staining red in Masson's trichrome method. In addition, haemorrhagic areas were get along with these cells (Figure 3).

Leiomyosarcomas are mesenchymal tumours, which in dogs are located particularly in the digestive tract and uterus. These tumours are uncommon in and around the eyes (1, 2, 4, 9, 11). In this case study, based on pathomorphological examination, a tumour located in the right conjunctiva of a dog was diagnosed as leiomyosarcoma. Generally, in domestic animals, vascular tumours, melanomas, squamous cell carcinomas and papillomas are encountered in and around the eyes. It is considered that chronic irritation and excessive exposure to sunlight are effective in the development of these tumours (5-8, 10). The surface of the tumour investigated

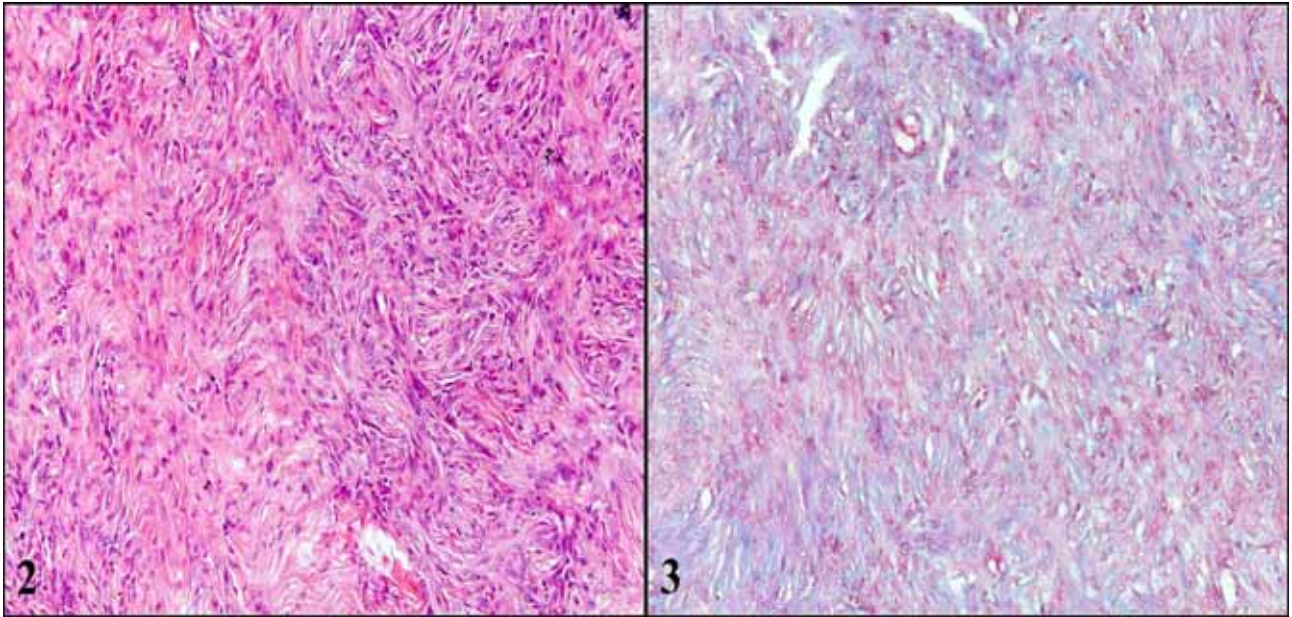
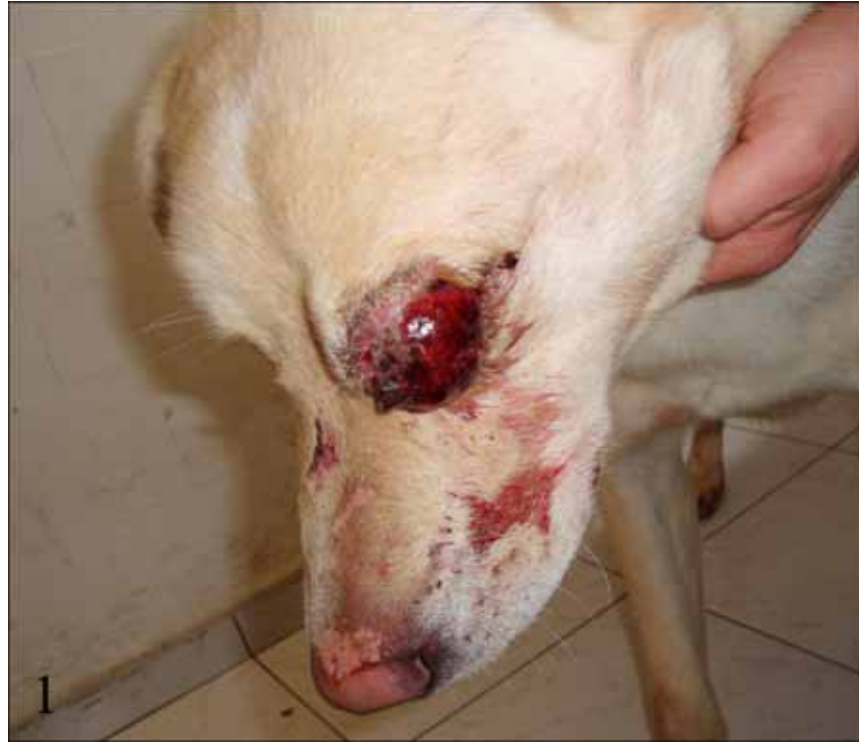

Figure 1. Appearance of the tumor in the left eye.

Şekil 1. Sol gözde tümörün görünümü.

Figure 2. Atypical muscle cells, spindle-shaped arrangement, H&E, x100.

Şekil 2. Bantlar şeklinde dizilim gösteren iğ şekilli atipik kas hücreleri, H&E, x100.

Figure 3. Red muscle cells, Masson's trichrome, x100.

Şekil 3. Kırmızı renkte boyanan kas hücreleri, Masson's trichrome, x100.

in this case study presenting with haemorrhages and ulcers, and histologically, the presence of inflammatory cells suggested that chronic irritation may have caused the development of the tumour. Although mesenchymal tumours are uncommon in and around the eyes, some literature reports indicate that neurofibromas may also be

encountered in the conjunctiva of dogs (4). Malignant tumours of the muscle tissue are encountered in many organs and tissues, including the gastrointestinal tract and urinary and genital systems (1-4, 9, 12). Limited information is available on leiomyosarcomas located in the conjunctiva. Histologically, the cells of these tumours

present with a high number of mitotic figures. In this case, in parallel with literature reports, many atypical mitotic figures were observed. In general, leiomyosarcomas develop slowly and rarely show a tendency of metastasis (2, 4, 9, 11, 12). In this case study, the general examination of the dog showed that no other tumour existed in the dog, apart from the mass located in the conjunctiva. Furthermore, no metastasis was detected in the postoperative period.

In conclusion, in view of this case having been detected in an animal younger than that indicated in literature reports and the leiomyosarcoma displaying conjunctival localisation, which is uncommon, this case study is considered to provide further insight for veterinary practitioners and future research.

References

1. **Cohen M, Post GS, Wright JC** (2003): *Gastrointestinal leiomyosarcoma in 14 dogs*. J Vet Intern Med, **17**, 107-110.
2. **Cooper BJ, Valentine BA** (2002): *Tumors of Muscle*. In: DJ Meuton, (ed), *Tumors in Domestic Animals*. 4 th ed. pp. 319-363. Iowa State Press, Iowa.
3. **Hayden DW, Klausner JS, Waters DJ** (1999): *Prostatic leiomyosarcoma in a dog*. J Vet Diagn Invest, **11**, 283-286.
4. **Kapatkin AS, Mullen HS, Matthiesen DT, Patnaik AK** (1992): *Leiomyosarcoma in dogs: 44 cases (1983-1988)*. J Am Vet Med Assoc, **201**, 1077-1079.
5. **McCowan C, Stanley RG** (2004): *Pigmented squamous cell carcinoma of the conjunctiva of a horse*. Vet Ophthalmol, **7**, 421-423.
6. **Moore CP, Collins BK, Linton LL, Collier LL** (2000): *Conjunctival malignant melanoma in a horse*. Vet Ophthalmol, **3**, 201-206.
7. **Multari D, Vascellari M, Mutinelli F** (2002): *Hemangiosarcoma of the third eyelid in a cat*. Vet Ophthalmol, **5**, 273-276.
8. **Murphy CJ, Bellhorn RW, Buyukmihci NC** (1989): *Bilateral conjunctival masses in two dogs*. J Am Vet Med Assoc, **195**, 225-228.
9. **Penninck DG** (1998): *Characterization of gastrointestinal tumors*. Vet Clin North Am Small Anim Pract, **28**, 777-797.
10. **Pirie CG, Knollinger AM, Thomas CB, Dubielzig RR** (2006): *Canine conjunctival hemangioma and hemangiosarcoma: a retrospective evaluation of 108 cases (1989-2004)*. Vet Ophthalmol, **9**, 215-226.
11. **Reis-Filho JS, Gonçalves C, Gärtner F** (2003): *Rectal leiomyosarcoma in a dog and review of gastrointestinal stromal tumours*. Vet Rec, **153**, 215-217.
12. **Sato T, Aoki K, Shibuya H, Machida T, Watari T** (2003): *Leiomyosarcoma of the kidney in a Dog*. J Vet Med, **50**, 366-369.

Geliş tarihi: 21.08.2013 / Kabul tarihi: 31.10.2013

Address for correspondence:

Nihat Yumusak
Harran University,
Faculty of Veterinary Medicine
Department of Pathology,
63000, Sanliurfa-TURKEY
e-mail: nihatyumusak@gmail.com.tr