

Short Communication / Kısa Bilimsel Çalışma

## Severe *Myocoptes musculus* infestation and treatment in laboratory mice

Sima SAHINDURAN<sup>1</sup>, Ozlem OZMEN<sup>2</sup>, Mehmet HALIGUR<sup>2</sup>, Bayram Ali YUKARI<sup>3</sup>

<sup>1</sup> Department of Internal Medicine, <sup>2</sup>Pathology and <sup>3</sup>Parasitology, Faculty of Veterinary Medicine, University of Mehmet Akif Ersoy, Burdur, Turkey.

**Summary:** A contagious disease characterized with severe pruritis, weight loss and alopecia was observed in laboratory mice in Experimental Animal Breeding Unit in University of Akdeniz, Turkey, after recently transferring the animals from Israel. Twenty out of 100 mice were referred to the clinics of the Department of Internal Medicine, Faculty of Veterinary Medicine University of Mehmet Akif Ersoy, for a diagnosis. Alopecia and severe itching were observed all over the body, particularly on the abdominal area. Skin scrapings were obtained from affected sites of the skin for a parasitological examination. At the examination of the skin scrapings, treated with 10 % of potassium hydroxide, numerous mite agents and eggs were observed. Agents were diagnosed as *Myocoptes musculus* according to their morphological characteristics. Five mice were euthanatized and examined pathologically. At the histopathological examination of the skin samples taken from alopecia and pruritic areas, numerous mite agents were seen in the tunnels in the epidermis. Mild inflammatory reaction including lymphocyte and neutrophil leukocytes were observed in the dermis. After diagnosis, mice were treated with ivermectin (Vilmectin) solution via drinking water (8 mg/L drinking water once a week for 3 wks). All animals were successfully recovered after the treatment.

Key words: Ivermectin, mice, *Myocoptes musculus*.

### Laboratuvar farelerinde şiddetli *Myocoptes musculus* enfestasyonu ve sağaltımı

**Özet:** Akdeniz Üniversitesi deney hayvanları ünitesine İsrail'den getirilen laboratuvar farelerinde deride şiddetli kaşıntı, kilo kaybı ve alopesiyle karakterize bir hastalık saptandı. Yüz fareden 20'si teşhis için Mehmet Akif Ersoy Üniversitesi Veteriner Fakültesi İç Hastalıkları Anabilim Dalına getirildi. Bütün vücutta özellikle karın bölgesinde alopesi ve kaşıntı gözlemlendi. Parazitolojik muayene için kaşıntılı bölgelerden deri kazıntısı alındı. Potasyum hidroksit ile (%10'luk) muamele edilen deri kazıntılarının parazitolojik incelemesinde çok sayıda akar ve yumurtalarına rastlandı. Akarlar morfolojik karakterlerine göre *Myocoptes musculus* olarak teşhis edildi. Farelerden beşi ötenazi edilerek patolojik olarak incelendi. Kaşıntılı ve alopesik sahalardan alınan deri örneklerinin histopatolojik yoklamasında epidermisteki tüneller içerisinde çok sayıda akar'a rastlandı. Dermiste lenfosit ve nötrofil lökositlerden oluşan hafif yangısal reaksiyon saptandı. Teşhisten sonra fareler, içme sularına ivermectin solusyonu (Vilmectin) 8 mg/L dozunda karıştırılarak haftada 1 kez olmak üzere üç defa verilerek tedavi edildi. Sağaltımdan sonra hayvanların tümü iyileşti.

Anahtar sözcükler: Fare, ivermectin, *Myocoptes musculus*.

A large number of mites species have been reported in wild rodents, but the infection in laboratory animals is becoming very rare. Of the many mites of the mouse described, only the fur mites *Myobia musculi* and *Myocoptes musculus* have much pathogenic potential (4,8). The major infectious causes of alopecia and dermatitis have been associated with fur mites. Generalized thinning of the hair, especially on difficult-to-groom areas such as the head and trunk, is seen in the infestation. The coat often appears greasy and in cases of heavy infestation mice are noticeably pruritic with self-inflicted dermal ulcers (5).

The mites burrow in the deeper parts of the stratum corneum or the superficial layers of the stratum malpighii of the skin and rarely go deeper. It completes its entire

cycle at this level. Even in this superficial position, however, the mites cause severe itching, hyperkeratosis, and acanthosis, and loss of hair or wool results (7).

Ivermectin in drinking water at dilutions of 1 ml/L (10 micrograms of ivermectin/ml) (9) or ivermectin 0.2 mg/kg SC or PO twice at 1 day intervals are successful against *Myocoptes musculus* mite in natural infected laboratory mice (5).

The aim of the present study was to describe the clinical and laboratory findings and also the treatment of naturally occurring *Myocoptes musculus* infestation in laboratory mice.

Twenty mice (13, Balb/c and 7, C57 mice) from Akdeniz University Experimental Animal Breeding Unity consisting of approximately 100 mice were brought to

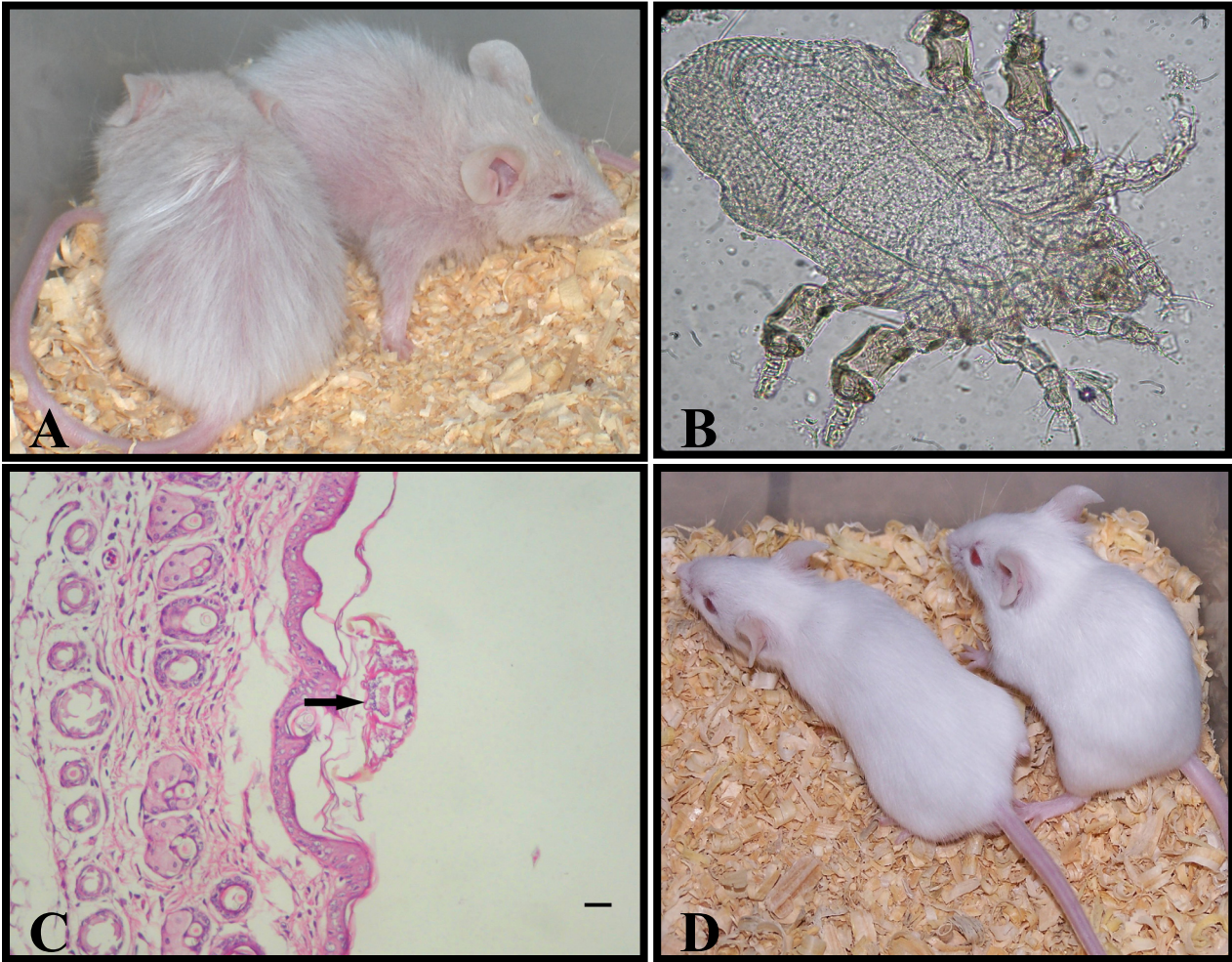


Figure-1: A: Severe alopecia and weight loss in affected mice, B: Female *Myocoptes musculus*, C: Histopathological appearance of the skin and adult *Myocoptes musculus* (arrow) Bar=200µm, D: Healthy mice after treatment.

Şekil-1: A: Enfekte farelerde şiddetli alopecia ve kilo kaybı, B: Dişi *Myocoptes musculus* C: derinin histopatolojik görünümü ve olgun *Myocoptes musculus* (ok) HE, Bar=200µm, D: Sağaltım sonrası sağlıklı farelerin görünümü.

the Department of Internal Medicine with pruritis and weight loss symptoms. The ages of the affected mouse were ranged from 1-3 month and all animals had a history of more than 3 weeks of disease. Blood samples were collected in 5 mice from the tail veins. MS9 blood counting equipment (MELET SCHLOESING Laboratories, FRANCE) was used for hematological analysis of the blood drawn in EDTA tubes.

Skin scrapings were taken from 5 mice with a blade, dissolved in potassium hydroxide for microscopical examination and for the presence of mites and lice, and then euthanized individually with ether in a glass container for histopathological examination. Tissue samples were collected from the mice after euthanasia and necropsy were performed. For histopathological examination, tissue samples were fixed in 10% buffered formalin and processed routinely for light microscopy. Five micron thick sections were taken from paraffin embedded tissues and stained with Hematoxylin-Eosin (HE). Animal were treated with ivermectin (Vilmectin)

solutions in drinking water (8 mg/L drinking water once a week for 3 wk).

Totally 100 mice (50 Balb/c and 50 C- 57 BL) were housed in Experimental Animals Breeding Unit of Faculty of Medicine, University of Akdeniz for research purposes and manufacture of biological products for medical use. In all of animals, clinical signs noted were alopecia (Fig.1A), intensive pruritis, erythema and weight loss after transport. The age of the affected mice ranged from 1-3 month and all animals had a history of more than 3 weeks of disease. Clinically, alopecia, severe itching and weight loss were the most prominent findings. Five out of the 100 animals were examined. Hematological observations revealed leukopenia, lymphopenia and granulocytosis. The mean leukocyte level of the affected animals was  $3.45 \pm 1.11 (x10^9/L)$ , lymphocyte 37 %- 59% and granulocyte  $57.8 \pm 3.45 (x10^9/L)$ .

*Myocoptes musculus* mites were detected from the skin scrapings of the affected animals. Adult females are

elongated ventrally, about 300 µm in length, and the propodosomal body striations have spine-like projections. The genital opening is a transverse slit. The anal opening is posterior and ventral. Legs I and II are normal, possessing short- stalked, flap- like pretarsi. Legs III and IV are highly modified for clasping hair (10). They were identified by means of morphological characteristics (Fig.1B) and numerous eggs of the agents were seen in the skin scraping. At the histopathological examination of the skin the mites were burrow in the deeper parts of the stratum corneum. Numerous mange agents were seen in the tunnels on the epidermis, and several adult agents were observed on the skin (Fig.1C). The mites were caused severe itching, hyperkeratosis, acanthosis and loss of hair. Mild inflammatory reaction including lymphocyte and neutrophil leukocyte were observed in the dermis.

Animals were treated with ivermectin (Vilmectin) solutions in drinking water (8 mg/L drinking water once a week for 3 wk). After treatment any skin lesion or pruritis were not observed and a skin scarping done one week after the treatment was negative for *Myocoptes musculinus* (Fig.1D).

*Myocoptes musculinus* mite causes myocoptic mange in wild and laboratory mice (10). Infestation may be asymptomatic or symptomatic cases wasting, pruritis, patchy alopecia which may be extensive and accumulation of fine bran-like material, mostly over affected areas can be seen. Self-trauma to the point of excoriation and secondary pyoderma can also be observed (6). In our study skin scarping demonstrated *Myocoptes musculinus* infestation and clinical symptoms were pruritis, erythema, alopecia and weight loss.

Mite infestation has reportedly caused lymphocytopenia, granulocytosis, increased production of IL-4 and decreased production of IL-2. These immunologic changes are consistent with a Th2-type response, with marked systemic consequences (1, 3). Lymphocyte levels were observed very low and granulocyte levels were very high in mice with *Myocoptes musculinus* in this study. These were attributed to the allergic reaction due to *Myocoptes musculinus* mites.

Ivermectin has been reported as a highly potent, broad-spectrum and systemic antiparasitic drug (2). In this study all animals were treated with ivermectin orally and after treatment mites were disappeared in skin scrapings.

As a result, severe mange infestation can be seen in laboratory mice under stress and can be successfully treated with ivermectin.

## References

1. **Baker DG** (1998): *Natural pathogens of laboratory mice, rats, and rabbits and their effects on research*. Clin Microbiol Rev, **11**, 231–266.
2. **Campbell WC** (1985): *Ivermectin, AN update*. Parasitology Today, **1**, 10-16.
3. **Csiza CK, McMartin DN** (1976): *Apparent acaridal dermatitis in a C57BL/6 Nya Mouse colony*. Lab Anim Sci, **26**, 781-787.
4. **Dinçer Ş** (1987): *Studies on the occurrence of mites of albino mice and rats, and their control*. Ankara Univ Vet Fak Derg, **35**, 389-406.
5. **Donnelly TM** (2004): *Disease problems of small rodents. In: Ferrets, Rabbits, and Rodents Clinical Medicine and surgery*. 2<sup>nd</sup> edition. Quesenberry KE. Carpenter JW Saunders, USA.
6. **Flynn RJ** (1973): *Parasites of laboratory animals*. Ames: Iowa State University Pres. Fox, Anderson, et al 2<sup>nd</sup> edition: Laboratory Animal Medicine.
7. **Jones TC, Hunt RD, King NW** (1997): *Disease caused by parasitic helminths and arthropods*. pp 677. In: Veterinary Pathology, Pennsylvania. Williams & Wilkins.
8. **Lallon M T** (1996): *Rats and mice*. 1-38. In: Handbook of Rodent and Rabbit Medicine. 1<sup>st</sup> edition. Laber-Laird, K.; Swindle; M.M.; Flecknell, P. Pergamon veterinary handbook series. Elsevier UK.
9. **Papini R, Marconcini A** (1991): *Treatment with ivermectin in drinking water against Myobia muscoli and Myocoptes musculinus mange in naturally infected laboratory mice*. Angew Parasitol, **32**, 11-13.
10. **Wall R, Shearer D** (1997): *Veterinary Entomology*. Chapman & Hall, London.

Geliş tarihi: 03.06.2008 / Kabul tarihi: 25.11.2008

## Address for correspondence

Dr. Sima Sahinduran  
Department of Internal Medicine,  
Faculty of Veterinary Medicine,  
University of Mehmet Akif Ersoy  
15100/Burdur- Turkey  
sahinduran@mehmetakif.edu.tr