

## Comparison of the volume fraction values of grey matter on the cervical enlargement of the spinal cord in chicken and quail\*

Caner BAKICI<sup>1</sup>, Çağdaş OTO<sup>1</sup>, Okan EKİM<sup>1</sup>, Ozan AHLAT<sup>2</sup>, Doğukan ÖZEN<sup>3</sup>, Ahmet ÇAKIR<sup>1</sup>

<sup>1</sup>Department of Anatomy, Faculty of Veterinary Medicine, Ankara University, Ankara, Turkey; <sup>2</sup>Department of Pathology, Faculty of Veterinary Medicine, Ankara University, Ankara, Turkey; <sup>3</sup>Department of Biostatistics, Faculty of Veterinary Medicine, Ankara University, Ankara, Turkey.

**Summary:** The aim of this study was to estimate and compare volume fraction values of grey matter (substantia grisea) in the cervical enlargement (intumescentia cervicalis) using stereological methods for two different types of birds. Ten pairs of quails and chickens were included in this study as one of them is flying and the other one is flightless bird species. The tissues cut into serial sections of 5 µm thickness were selected according to systematic random sampling and stained with cresyl violet. Volume and volume fractions were calculated in accordance with the Cavalieri principle. Student's t-test was used to evaluate volume fraction differences among the species. The volume fractions of grey matter in cervical enlargement of chicken and quail were  $0.277 \pm 0.005$  and  $0.346 \pm 0.014$  (Mean  $\pm$  Standart Deviation), respectively ( $p < 0.001$ ). There was a significant difference between chicken and quail cervical enlargements in terms of volume fraction values of grey matter. On the other hand, the Cavalieri principle was considered as an unbiased, accurate and effective method for volume and volume fraction estimations.

Keywords: Cavalieri principle, cervical enlargement, chicken, quail, volume fraction.

### Tavuk ve bildircında medulla spinalis'in intumescentia cervicalis'inde gri cevher hacim fraksiyon değerlerinin karşılaştırılması

**Özet:** Bu çalışmanın amacı, stereolojik yöntemler kullanarak iki farklı kuş türünün cervical genişlemesindeki (intumescentia cervicalis) gri cevherin (substantia grisea) hacim fraksiyon değerlerini hesaplamak ve karşılaştırmaktır. Araştırmaya biri uçabilen, diğeri uçamayan kanatlı türü olarak on adet bildircın ve on adet tavuk dahil edildi. Dokulardan 5 µm kalınlığında alınan seri kesitler, sistematik rastgele örnekleme kuralına göre seçildi ve cresyl violet ile boyandı. Hacim ve hacim fraksiyon değerleri Cavalieri prensibine göre hesaplandı. Türler arasındaki hacim fraksiyon farklılığını değerlendirmek için student's t testi kullanıldı. Tavuk ve bildircının cervical genişlemedeki gri cevher hacim fraksiyon değerleri sırasıyla,  $0.277 \pm 0.005$  and  $0.346 \pm 0.014$  (Ortalama  $\pm$  Standart Sapma) olarak belirlendi ( $p < 0.001$ ). Tavuk ve bildircının cervical genişlemelerinin gri cevherine ait hacim fraksiyon değerleri arasında önemli bir fark bulundu. Bunun yanı sıra, hacim ve hacim fraksiyonu tahminleri için Cavalieri prensibinin tarafsız, doğru ve etkili bir yöntem olduğu görüldü.

Anahtar sözcükler: Bildircın, Cavalieri prensibi, hacim fraksiyon, intumescentia cervicalis, tavuk.

### Introduction

Avian spinal cord differs from mammals' due to its outstretched location through the entire vertebral canal, relatively thin and long morphology and not forming the cauda equina (7). As in mammals, cervical enlargement is located along the length of the spinal cord (15). It is mentioned that it occupies last two cervical and the first or first two thoracic segments in domestic avian species. Nerves that innervate the wings originate from this unique structure (18).

In recent years, stereological methods have frequently been used in the estimation of morphometric

measurements on complex biological structures. Unbiased, realistic and quantitative results can be obtained (6, 11, 23). One of these methods used for volumetric estimations of structures is the Cavalieri principle (20).

Area or volume measurements of white matter and grey matter on sections of spinal cord had been determined by various stereological methods in human (14, 25), horse (1, 5) and rat (21, 23). However, stereological researches focused on the avian central nervous system are quite limited (4, 29). Any study conducted on the volume estimation of avian cervical enlargement itself using the Cavalieri principle couldn't be found.

\* This study was prepared from PhD thesis entitled "Stereological studies on the spinal cord of the chicken (*Gallus gallus domesticus*) and quail (*Coturnix coturnix*)" of the first author.

The aim of this study is to estimate and compare volume fraction values of the grey matter of cervical enlargement using the Cavalieri principle in two bird species as one of them is flying and the other one is flightless. And this estimation would help us to comment if the volume fraction of grey matter in cervical enlargement is an effective parameter between flying and flightless birds.

### Materials and Methods

The material of this study consisted of ten adult female chickens and ten adult female Japanese quails. All experimental procedures were approved by the Ankara University Local Ethics Committee for Animal Experiments (53184147 - 50. 04 / 58 - 10236). The animals were anesthetized by administration of ketamine hydrochloride (50 mg/kg, i. m.) and euthanized by sodium pentobarbital (150 mg/kg, i. v.).

Body weights and cervical enlargement weights before and after fixation were measured in chicken and quail. The related data were indicated in Table 1. Following the identification of cranial and caudal borders which were the middle point of 12 - 13 and 17 - 18 spinal nerves for chicken and 11 - 12 and 15 - 16 spinal nerves for quail respectively, cervical enlargements were dissected out from the vertebral canal before fixation process. Samples were weighed using precision balance (Radwag WPS 600 / c / 2, Poland). Cranio - caudal length and latero - lateral dimension of the midpoint of the tissue were measured with a digital caliper (Mitutoyo Series 500, Japan). Furthermore, the volumes of the cervical enlargements were calculated with a classical method, Archimedes principle that the volume of displaced water is equivalent to the volume of an organ fully immersed in a water (1).

Samples were soaked in the 10% buffered formalin solution for 15 days at room temperature and the same

measurements were applied to determine the shrinkage coefficient (26). Serial sections of 5 µm thickness were obtained from the blocks (Leica RM 2245, Germany) passed through the vacuumed benchtop tissue processor (Leica TP 1020, Germany). In accordance with the systematic random sampling, one of 200 and one of 100 sections were selected for each chicken and quail individuals, respectively. Therefore, 40 - 42 sections for chickens and 35 - 36 sections for quails were obtained.

Selected sections were stained with cresyl violet (Merck, Germany) (0.125%). Volume estimations were performed using the Cavalieri probe of the Stereo Investigator Software (Version 10.50, MBF Bioscience, USA) with the help of a computerized light microscope (Leica DM 4000 B, Germany) and a digital camera (CX 9000, MBF Bioscience, USA). The distance between two points assigned by point counting grid for each section in chicken and quail were determined as 300 µm and 200 µm (Figure 1), respectively.

The volume calculations were carried out by the following formula;

$$V = A_p \times m \times t \times (\sum P)$$

In the equation; "V" represents volume of the focused sample, "m" is section evaluation range, "A<sub>p</sub>" is the area of each point on the point counting grid, "t" is cross section thickness and "P" is the number of points at the desired region in section (8, 9).

The volume fraction is defined as the volumetric ratio of a specified structure to whole structure as indicated below. This volume fraction value should be between 0 and 1. The volume fractions of white matter and grey matter were calculated using the following equation (11, 25, 29).

$$V_{(x,y)} = \text{Volume of X phase in Y reference phase} / \text{Volume of Y reference phase}$$

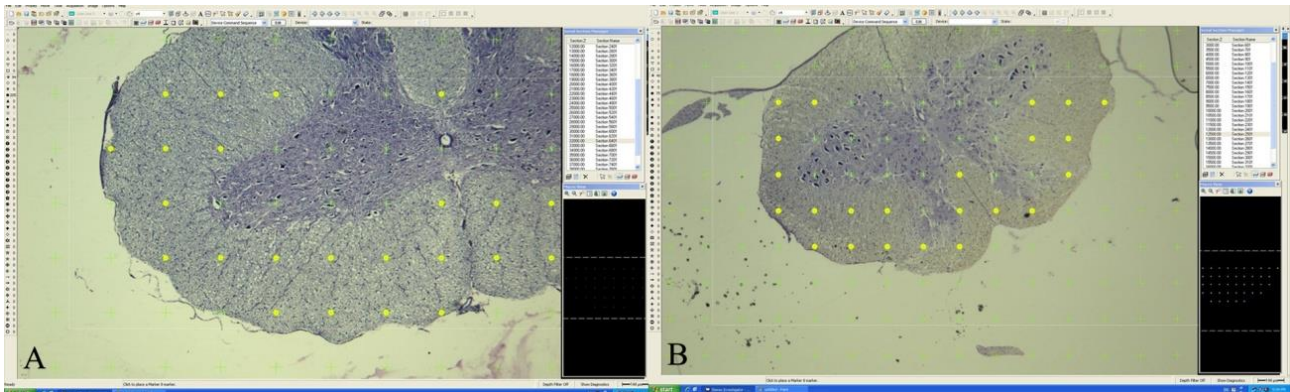


Figure 1. Calculations of the volume of white matter and grey matter by using point counting grid on section of chicken (A) and quail (B).

Şekil 1. Tavuk (A) ve bildırcın (B) kesiti üzerinde noktalı alan cetveli ile gri cevher ve beyaz cevherin hacim hesaplaması.

The coefficient of error (CE) for obtained data was calculated by stereo investigator program in order to see the reliability of the Cavalieri principle (9). CE values over 0.05 were not included in the study.

Before performing the statistical analysis, data were examined with Shapiro - Wilk test for normality and Levene test for homogeneity of variances as parametric test assumptions. Descriptive statistics for each variable were calculated and presented as "Mean  $\pm$  Standard Deviation". Student's t-test was used to evaluate the difference between chicken and quail for the proportion of cervical enlargement weight to body weight before fixation. Also, white matter and grey matter volume fractions calculated by the Cavalieri principle were analyzed with the student's t-test, as well as the cranio - caudal and latero - lateral shrinkage parameters. General linear model for repeated measurement procedure was used to evaluate the difference between chicken and quail among volumetric measurements. Advanced stage testing was only carried out for significant interactions and was performed using simple effect analysis. A probability value of less than 0.05 was considered as significant unless otherwise noted. All statistical analyses were performed by using SPSS 14.01 statistical software.

## Results

The average ratio of cervical enlargement weights before fixation to body weights were  $0.01215 \pm 0.0005$  and  $0.03221 \pm 0.00267$  in chicken and quail respectively. The difference between the two species was statistically significant ( $p < 0.001$ ) (Table 1).

Cranio - caudal and latero - lateral lengths of the cervical enlargements were calculated before and after fixation for two species. The decrease in cranio - caudal and latero - lateral lengths of tissues after fixation was statistically significant for both species ( $p < 0.001$ ) (Table 2). While the difference in the length of cranio - caudal shrinkage ratios was statistically significant ( $p = 0.003$ ) among the species, the difference in latero - lateral values was not statistically significant ( $p = 0.246$ ) (Table 3).

All CE values were below 0.05 for the volume estimations of white matter and grey matter of cervical enlargements calculated by the Cavalieri principle in chicken and quail. The most prominent result for our study is that the value of grey matter volume fraction of quail was higher than in chicken and the difference was statistically significant ( $p < 0.001$ ). Thus, the value of white matter volume fraction was higher in chicken as compared to quail and the difference was statistically significant ( $p < 0.001$ ) (Table 4).

There was a notable decrease in the volume of cervical enlargement before and after fixation and after staining procedure when each group was compared within itself. The differences between the measured values were statistically significant ( $p < 0.001$ ) (Table 5). As shrinkage parameters were compared among the species, there was also a certain decrease in the volume for any process applied on the tissue. However, there was no statistically significant difference in the shrinkage parameters among two species in each stage ( $p > 0.05$ ) (Table 6).

Table 1. Body and cervical enlargement weights of the chicken and quail (mean  $\pm$  SD).

Tablo 1. Tavuk ve bıldırcına ait vücut ağırlığı ile cervical genişleme ağırlıkları (ortalama  $\pm$  standart sapma).

Species	Body weight	Cervical enlargement weight before fixation (g)	Cervical enlargement weight after fixation (g)	Weight ratio of the cervical enlargement to body
Chicken	2609.08 $\pm$ 11.015	0.317 $\pm$ 0.013	0.336 $\pm$ 0.011	0.01215 $\pm$ 0.0005
Quail	161.480 $\pm$ 1.062	0.052 $\pm$ 0.004	0.057 $\pm$ 0.005	0.03221 $\pm$ 0.00267*

\*An asterisk indicates a significant difference between groups within the same column ( $p < 0.001$ ) (n = 10).

\* Yıldız işareti, aynı sütundaki gruplar arasında önemli bir fark olduğunu gösterir ( $p < 0.001$ ) (n = 10).

Table 2. Length and wide of the cervical enlargement before and after fixation (mean  $\pm$  SD).

Tablo 2. Tespit öncesi ve sonrası cervical genişlemenin uzunluk ve genişlik değerleri (ortalama  $\pm$  standart sapma).

	Species	(mean $\pm$ SD)	p
Cranio-caudal length of the cervical enlargement before fixation (mm)	Chicken	50.66 $\pm$ 0.41	< 0.001
	Quail	20.29 $\pm$ 0.46	
Cranio-caudal length of the cervical enlargement after fixation (mm)	Chicken	44.35 $\pm$ 0.67	< 0.001
	Quail	18.09 $\pm$ 0.21	
Latero-lateral wide of the cervical enlargement before fixation (mm)	Chicken	6.01 $\pm$ 0.27	< 0.001
	Quail	5.64 $\pm$ 0.33	
Latero-lateral wide of the cervical enlargement after fixation (mm)	Chicken	3.02 $\pm$ 0.14	< 0.001
	Quail	2.8 $\pm$ 0.1	

(n = 10)

Table 3. Shrinkage ratio of the length and wide of the cervical enlargement before and after fixation (%).

Tablo 3. Tespit öncesi ve sonrası cervical genişlemenin uzunluk ve genişlik değerlerindeki büzüşme oranları (%).

	Species	(mean ± SD)	p
Shrinkage ratio of the cranio-caudal length of the cervical enlargement	Chicken	12.45 ± 0.99	0.003
	Quail	10.79 ± 1.12	
Shrinkage ratio of the latero-lateral wide of the cervical enlargement	Chicken	6.19 ± 2.30	0.246
	Quail	7.35 ± 2.02	

(n = 10)

Table 4. Mean volume fractions and volumes of white matter and grey matter, mean point number, mean coefficient of error and mean number of sections of chicken and quail.

Tablo 4. Gri ve beyaz cevherin ortalama hacim ve hacim fraksiyon değerleri, ortalama sayılan nokta sayısı, ortalama hata katsayısı ve tavuk ve bıldırcındaki ortalama kesit sayısı.

	Chicken	Quail
Volume of the white matter (mm <sup>3</sup> ) (mean ± SD)	190.47 ± 4.5	28.61 ± 1.49
Mean point number	2116	1450
Mean CE	0.01	0.011
Volume of the grey matter (mm <sup>3</sup> ) (mean ± SD)	72.99 ± 2.4	15.11 ± 0.96
Mean point number	811	763
Mean CE	0.012	0.013
Volume fraction of the white matter	0.723	0.654*
Volume fraction of the grey matter	0.277	0.346*
Mean number of cross sections	41	35

\*An asterisk indicates a significant difference between groups within the same row (p &lt; 0.001) (n = 10).

\* Yıldız işareti, aynı satırdaki gruplar arasında önemli bir fark olduğunu gösterir (p &lt; 0.001) (n = 10).

Table 5. Volumes of the cervical enlargement of chicken and quail calculated by Archimedes principle before and after fixation and Cavalieri principle (mean ± SD).

Tablo 5. Tavuk ve bıldırcında tespit öncesi ve sonrası Arşimed ve Cavalieri prensibi ile hesaplanan cervical genişlemenin hacim değerleri (Ortalama ± standart sapma).

	Chicken	Quail
Volume before fixation (mm <sup>3</sup> )	510 ± 24.04	86 ± 10.75
Volume after fixation (mm <sup>3</sup> )	310 ± 10.54	50 ± 3.33
Volume with Cavalieri principle (mm <sup>3</sup> )	263.46 ± 6.29*	43.72 ± 2.08*

\*An asterisk indicates a significant difference between groups within the same column (p &lt; 0.001) (n = 10).

\* Yıldız işareti, aynı sütundaki gruplar arasında önemli bir fark olduğunu gösterir (p &lt; 0.001) (n = 10).

Table 6. Volumetric shrinkage ratios of chicken and quail (%).

Tablo 6. Tavuk ve bıldırcında hacimsel büzüşme oranları (%).

	Species	(mean ± SD)	p
Between before and after fixation	Chicken	39.16 ± 1.9	0.272
	Quail	41.32 ± 5.6	
Between after fixation and Cavalieri principle	Chicken	14.97 ± 1.93	0.072
	Quail	12.41 ± 3.67	
Between before fixation and Cavalieri principle	Chicken	48.29 ± 1.26	0.92
	Quail	48.5 ± 6.4	

(n = 10)

## Discussion and Conclusion

Although there a wide range of studies evaluating the use of one or combined stereological methods on the spinal cord (17, 19, 22, 27, 30), stereological studies focused on the avian spinal cord is quite limited (4, 29). Besides, no stereological study, particularly about the cervical enlargement region, obtained the similar content with the one found in our research.

Previous studies have indicated that the partial fractions of white matter and grey matter differ on the various transversal sections of the spinal cord (10, 23). In addition to that, Baumel (3) reported that the cervical enlargement region of flying birds may be larger. These are the main reasons why we prefer chicken and quail as a material in this study. It has been pointed out that the cervical part of the spinal cord was frequently exposed to surgical interventions in humans (29) and potential therapeutic agents could be useful for examining the recovery stages of damage in the cervical and thoracic region (27). In this context, avian subjects could be a convenient animal model for this kind of researches.

In this study, the volume fraction value of the grey matter in quail which is a flying and a migratory bird as well is significantly higher when compared to chicken. This finding is verifying our hypothesis. On the other hand, the volume fraction ratio could also be evaluated in terms of neuron numbers in the grey matter and this concept will form our next study. Findings in the 6<sup>th</sup> cervical region of chicken that Turgut et al. (29) indicated in their study were close to those in our research. However, there are some regional differences on the spinal cord among the studies.

Haziroglu et al. (10) calculated the ratios of white matter and grey matter by using different methods in their study. However, when calculating these ratios, they didn't give exact information about the sections examined and the criteria on the selection of sections. In our study, the entire cervical enlargement was evaluated and sections were obtained in accordance with systematic random sampling rules.

Some studies stated that stereological methods with computer-assisted calculations overcome the difficulty of volume estimation of complex anatomical structures (11, 16, 29). In accordance with that statement, computer-assisted calculation was quite convenient and the Cavalieri principle could easily be applied for the volume fraction analyses in our study.

Turgut et al. (29) reported that the mean CE for white and grey matter were 0.02 and 0.03 and the mean point numbers were 271 and 639 respectively. By comparison with Turgut et al. (29), we obtained lower CE values in our study. This might probably occur due to the high

frequency of the sampling intervals, the measurement value used in the point counting grid and the total number of counts.

Although there are various staining methods designed for the nervous system (2), the cresyl violet staining comes to the forefront among them. While Siriphorn et al. (27) applied cresyl violet staining to see Nissl bodies, Portiansky et al. (23) preferred the same method for the spinal cord sections. The cresyl violet staining protocol in our study was quite close to Siriphorn et al. (27) and white matter and grey matter could easily be distinguished from each other.

During fixation or histological processes, shrinkage or enlargement on the weight, length or volume of any tissue is a known fact (12, 13, 24). An increase in the tissue weight due to the fixative solution used in our study was also noticed as described by Quester and Schröder (24). However, a direct comparison among the studies (12, 13, 24) in terms of alterations could be misleading because the parameters such as formalin concentration, fixation period and the exact measurement time of tissues are quite variable.

The shrinkage values on cranio - caudal length in our study were similar to those obtained by Bahar et al. (1) but not Quester and Schröder (24). On the other hand, it was noticed that the shrinkage values obtained from latero - lateral width were different from the mentioned studies (1, 24). This is thought to have been caused by the size of the tissue or the mechanic effect of the container during fixation. Also, it has been mentioned that gravity had an effect on the transverse diameter of fixated tissues (28).

Alterations on volume as well as length are observed during fixation. Researchers have already indicated that different fixative solutions, different staining methods or processes that are applied to tissue, caused different changes in tissues (1, 23). Herein the results obtained from our study are different from Bahar et al. (1). The reasons for this difference are the size of the tissue and to include the volumetric data measured before fixation.

As a conclusion, we can state that the volume fraction of grey matter in a flying bird is significantly higher when compared with a flightless bird. This difference in the volume fraction in the countenance of a flying bird will be examined in terms of neuron cell quantity in our further studies focused on various bird species.

## Acknowledgment

We wish to thank Associate Professor Sinan Yürüker for his technical support. This study received financial support from Ankara University Scientific Research Projects Unit (Project no: 13L3338006).

### References

1. **Bahar S, Bolat D, Selçuk ML** (2013): *The segmental morphometric properties of the horse cervical spinal cord: A study of cadaver*. Scientific World J, **2013**, 1-9.
2. **Bancroft JD, Gamble M** (2002): *Theory and Practice of Histological Techniques*. Livingstone Publishing, Edinburgh, England.
3. **Baumel JJ** (1975): *Aves Nervous System*. 437-448. In: CE Rosenbaum, NG Ghoshal, D Hillmann (Ed). Sisson's and Grossman's The Anatomy of The Domestic Animals. Philadelphia, Saunder, USA.
4. **Bolat D, Tıprıdamaz S** (2012): *The use of optical fractionator to estimate the total number of ependymal cells of the spinal cord in leghorn*. Kafkas Univ Vet Fak Derg, **18**, 129-133.
5. **Bolat D, Bahar S, Sur E, et al** (2012): *Selective gray and white matter staining of the horse spinal cord*. Kafkas Univ Vet Fak Derg, **18**, 249-254.
6. **Cahill MM, Kett MM, Mccausland JE, et al** (1996): *Glomerular stereology: Why, what and how to measure glomerular structure*. Nephrology, **2**, 305-313.
7. **Dinç G, Yılmaz S** (2002): *Sinir sistemi*. 157-185. In: N Dursun, (Ed). Evcil Kuşların Anatomisi. Medisan Yayınevi, Ankara, Türkiye.
8. **Garcia-Finana M, Cruz-Orive LM, Mackay CE, et al** (2003): *Comparison of MR imaging against physical sectioning to estimate the volume of human cerebral compartments*. Neuroimage, **18**, 505-516.
9. **Gundersen HJG, Jensen EB** (1987): *The efficiency of systematic sampling in stereology and its prediction*. J Microsc, **147**, 229-263.
10. **Haziroğlu RM, Orhan İÖ, Yıldız D, et al** (2001): *Morphology of the spinal cord in the chicken, duck and pigeon*. Turk J Vet Anim Sci, **25**, 913-920.
11. **Howard CV, Reed MG** (2005): *Unbiased Stereology*. Garland Science, Cornwall, England.
12. **Hsu PK, Huang HC, Hsieh CC, et al** (2007): *Effect of formalin fixation on tumor size determination in stage I non-small cell lung cancer*. Ann Thorac Surg, **84**, 1825-1829.
13. **Jonmarker S, Valdman A, Lindberg A, et al** (2006): *Tissue shrinkage after fixation with formalin injection of prostatectomy specimens*. Virchows Arch, **449**, 297-301.
14. **Ko HY, Park JH, Shin YB, et al** (2004): *Gross quantitative measurements of spinal cord segments in human*. Spinal Cord, **42**, 35-40.
15. **König HE, Liebich HG, Cerveny C** (2004): *Nervous system*. 465-536. In: HE König, HG Liebich, (Ed). Veterinary Anatomy of Domestic Mammals Textbook and Colour Atlas. Schattauer, Stuttgart, Germany.
16. **Kristiansen SL, Nyengaard JR** (2012): *Digital stereology in neuropathology*. Acta Path Micro Im A, **120**, 327-340.
17. **Lin JY, Peng B, Yang ZW, et al** (2011): *Number of synapses increased in the rat spinal dorsal horn after sciatic nerve transection: a stereological study*. Brain Res Bull, **84**, 430-433.
18. **Nickel R, Schummer A, Seiferle E** (1977): *Anatomy of the Domestic Bird*. Verlag Paul Parey, Hamburg, Germany.
19. **Nurcombe V, Wreford NG, Bertram JF** (1991): *The use of the optical disector to estimate the total number of neurons in the developing chick lateral motor column: effects of purified growth factors*. Anat Record, **231**, 416-424.
20. **Nurcombe V, Wreford NG, Bertram JF** (2001): *Stereological estimation of neuronal number: The optical disector / Cavalieri combination*. 251-268. In: RA Rush (Ed). Neurotrophin Protocols. Humana Press, Totowa, NJ, USA.
21. **Özyurt B, Kesici H, Alıcı SK, et al** (2011): *Prenatal exposure to diclofenac sodium changes the morphology of the male rat cervical spinal cord: A stereological and histopathological study*. Neurotoxicol Teratol, **33**, 282-287.
22. **Peng B, Lin JY, Shang Y, et al** (2010): *Plasticity in the synaptic number associated with neuropathic pain in the rat spinal dorsal horn: a stereological study*. Neurosci Lett, **486**, 24-28.
23. **Portiansky EL, Barbeito CG, Goya RG, et al** (2004): *Morphometry of cervical segments grey matter in the male rat spinal cord*. J Neurosci Meth, **139**, 217-229.
24. **Quester R, Schröder R** (1997): *The shrinkage of the human brain stem during formalin fixation and embedding in paraffin*. J Neurosci Meth, **75**, 81-89.
25. **Sastre-Garriga J, Ingle GT, Chard DT, et al** (2005): *Grey and white matter volume changes in early primary progressive multiple sclerosis: a longitudinal study*. Brain, **128**, 1454-1460.
26. **Schned AR, Wheeler KJ, Hodorowski CA, et al** (1996): *Tissue-shrinkage correction factor in the calculation of prostate cancer volume*. Am J Surg Pathol, **20**, 1501-1506.
27. **Siriphorn A, Dunham KA, Chompoopong S, et al** (2012): *Post injury administration of 17β-Estradiol induces protection in the gray and white matter with associated functional recovery after cervical spinal cord injury in male rats*. J Comp Neurol, **520**, 2630-2646.
28. **Tran T, Sundaram CP, Bahler CD, et al** (2015): *Correcting the shrinkage effects of formalin fixation and tissue processing for renal tumors: toward standardization of pathological reporting of tumor size*. J Cancer, **6**, 759-766.
29. **Turgut M, Tunç AT, Aslan H, et al** (2007): *Effect of pinealectomy on the morphology of the chick cervical spinal cord: A stereological and histopathological study*. Brain Res, **1129**, 166-173.
30. **Walloe S, Nissen UV, Berg RW, et al** (2011): *Stereological estimate of the total number of neurons in spinal segment D9 of the red-eared turtle*. J Neurosci, **31**, 2431-2435.

Geliş tarihi : 26.09.2017 / Kabul tarihi : 22.12.2017

#### Address for correspondence:

Dr. Caner BAKICI

Ankara University, Faculty of Veterinary Medicine

Department of Anatomy, 06110, Dışkapı, Ankara, Turkey

Tel: 90-5078315011

e-mail: vetcanerbakici@gmail.com