

**EIMERIA NINA-KOHL-YAKIMOVY YAKIMOV  
AND RASTEGAIIEFF, 1930 IN AN ANGORA GOAT**

**Fahri Sayın\***

Coccidiosis of domestic animals has been studied extensively but not in an equal degree in all species. Chicken coccidiosis, for example, has been studied a great deal, while coccidiosis in cattle, sheep and goats has received very little attention.

For a long time many authors have written about the danger of coccidiosis in sheep and goats <sup>1, 2, 3, 7, 8, 9, 11, 13, 14</sup>. According to several of them <sup>9, 16, 20</sup> mortality in lambs and kids from coccidiosis is 10 % to 90 % .In Turkey coccidiosis is wide spread among Angora goats, especially among the young animals, in which it causes emaciation, stunding and even death <sup>17</sup>. Little work has been done on the coccidiosis in Angora goats up to present time. This indicates that the coccidia and the disease they cause need to be studied in detail.

The oocyst of *Eimeria nina-kohl-yakimovi* has been described from sheep and gaots in many countries including Turkey <sup>2, 4, 5, 14, 15, 16, 17, 18, 21</sup>. The life cycle and pathogenecity of this species were also studied in sheep <sup>14</sup> and ordinary goats <sup>2</sup>. But no data on its pathogenecity and endogenous stage in Angora goats is available.

It is the purpose of the present paper to record the findings of a study on the endogenous stage of *Eimeria nina-kohl-yakimovi* and its oocyst in the kid of Angora goat.

**Material and Methods**

In May, 1963, several new-born kids of Angora goats have been purchased from Lalahan Animal Breeding Research Institute to study the pathogenecity and the endogenous development of *Eimeria parva* experimentally. One of the kids became ill one week before the begining of the experiment and began to discharge soft

---

\* Dr. Med. Vet., Faculty of Veterinary Medicine, Department of Protozoology, Arthropodology and Control of Parasitic Diseases. Ankara-Turkey.

feces and the oocyst of *Eimeria*. The oocysts excreted were pure and were identified as *Eimeria nina-kohl-yakimovi* Yakimof and Rastegaieff, 1930. The kid was sacrificed to study the endogenous stage of the parasite and the changes in the alimentary tract of the animal. Portions of the intestine and other organs were fixed in 10 % formalin and sections were stained with haematoxiline-eosine for histologic examination and fecal sample was prepared for further study. Fecal sample was mixed with 2.5 per cent Potassium Dichromate solution and placed in a thin layer in a petri dish for 2 weeks to permit the coccidian oocyst to sporulate. It was then stored in the refrigerator. The oocysts were concentrated by flotation with Sheather's sugar solution prior to examination. They were examined with a Leitz microscope equipped with apochromatic objectives. The pictures of the parasite were taken with Beck Microphotography apparatus.

### Results

Only one species of *Eimeria*, *Eimeria nina-kohl-yakimovi* Yakimof and Rastegaieff, 1930, was seen in the feces of the kid. The same species was also seen on the subsequent examination of fecal samples from other Angora goats in the herds in the vicinity of Ankara. Since there are apparently no complete detailed descriptions of the sporulated oocysts of *Eimeria nina-kohl-yakomavi* Yakimof and Rastegaieff, 1930 from Angora goats, these are given below.

The oocysts of this species were round, rarely short oval (Fig. 1). One hundred twenty five oocysts measured 21 to 28 by 18 to 24

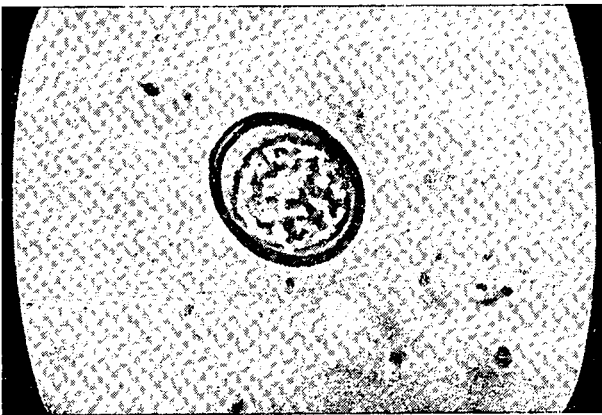


Fig. 1 : Unsporulated oocyst of *Eimeria nina-kohl-yakimovi*

microns with a mean of 24.1 by 21.1 microns. Their length-width ratio was 1.4 microns. The wall was smooth, double contoured, colorless, 1 to 1.5 microns thick. A micropyle was absent or imperceptible. There was no micropylar cap. Sporulation time was 60 hours at a temperature of 20 centigrade. The sporocysts were oval, round or egg shaped. They measured 4 to 12 by 4 to 7 microns. The sporozoites were comma-shaped or pear-shaped. An oocyst polar granule and oocyst residium were absent. A residual body in the sporocyst was present (Fig. 2).

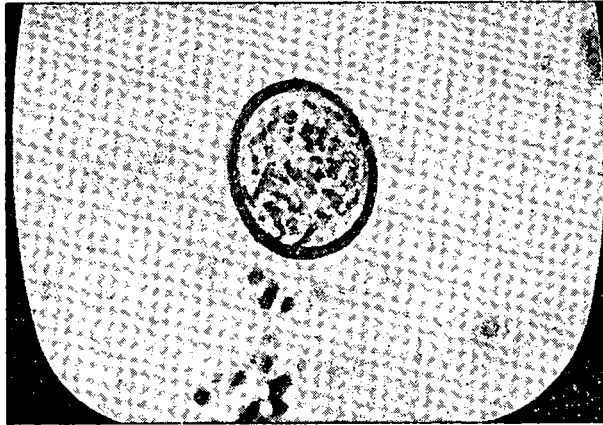


Fig. 2 : Sporulated oocyst of *Eimeria nina-kohl-yakimovi*.

This species of *Eimeria* was found to be present in 207 (23%) out of 900 Angora goats which were from the vicinity of Ankara.

*Pathologic changes:*

The gross lesions in the intestine consisted of numerous diffusely-scattered, round, smooth white plaques approximately 0.2 to 0.3 mm. in diameters in mucosa. The border of these lesions were distinct and regular in outline. The plaques themselves neither raised nor depressed below the surface of unaffected mucosa. The mucosa was slightly thickened throughout the intestine. Neither congestion, haemorrhage nor excess mucus were present. The feces of the kid was soft and did not contain blood. There was no haemorrhagic content in the intestine either.

Sections of small intestine, cecum and colon were examined. Slight to moderate enteritis was present. The cellular reaction consisted of lymphocytes and polymorphonuclear leucocytes. The pa-

parasites destroyed the epithelial cells in which they developed and caused the denudation of lamina epithelialis.

Numerous mature cocidian macrogametes, microgametocytes schizonts, oocysts were present in the epithelial cells of ileum, ce-cum and upper part of the large intestine. Merozoites were also seen in the smears were made of small intestine.

One type of schizont was present (Fig.3). They were ellipsoid or round in shape and measured 31 to 43 by 22 to 31 microns, with a mean of 37.0 by 26.5 microns. All of them contained the nuclei regularly distributed through the whole schizont. Each nuclei seems to be separated by a clear zone from the cytoplasma of schizont.

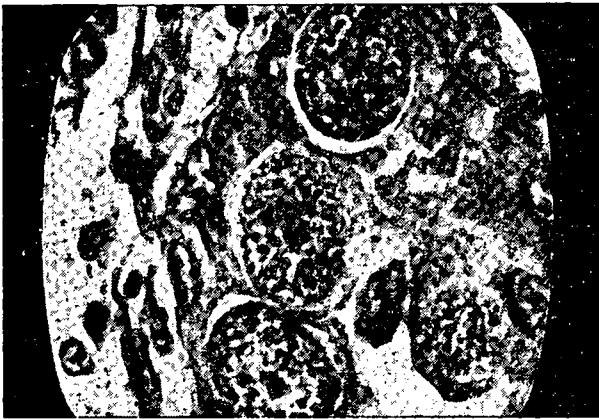


Fig. 3 : schizonts of *Eimeria nina-kohl-yakimovi*.

The merozoites were obtained in the fresh smears from the intestine of the kid (Figure 4). They were straight with one end rather bluntly rounded and other down more. They measured 11 by 1 microns. No free merozoites were found in the sections.

There were no early macrogametes but few mature ones were seen in the epithelial cells of the side of willi (Figure 5). The mature macrogametes contained a large number of granules about 1 micron in diameter. Their nucleus lay at the center of the cell. They measured 9 to 18 by 7 to 13 microns with a mean of 13.5 by 10 microns.

The nuclei in the microgametocytes scattered regularly and they were not separated by a clear zone from the cytoplasma of microgametocyte. The microgametes lay in whorls on the surface of

the microgametocytes, that is, when microgametes became mature,

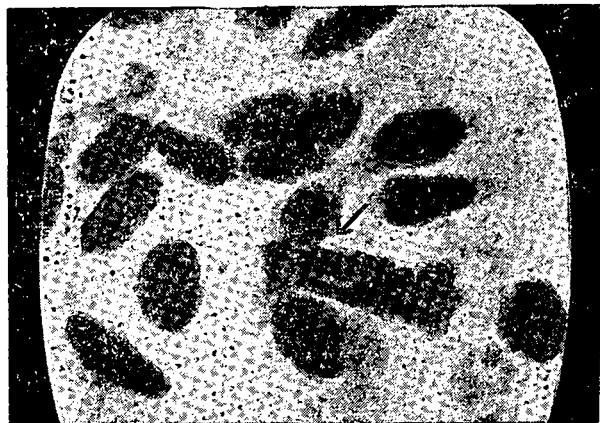


Figure 4. merozoite of *Eimeria nina-kohl-yakimovi*.

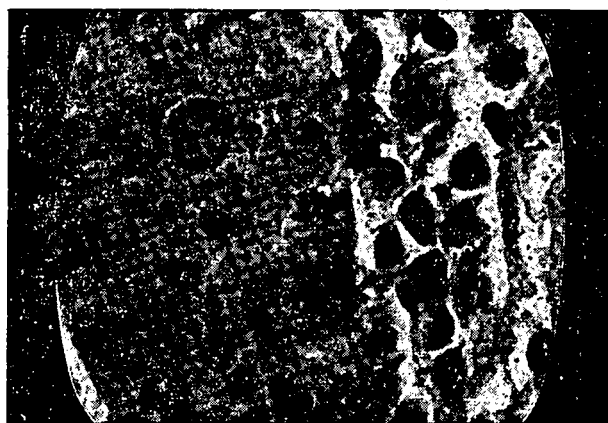


Figure 5. macrogametes of *Eimeria nina-kohl-yakimovi*.

some residual material remained in the center of the latter (Figure 6) The microgametocyte measured 20 to 25 by 15 to 18 microns with a mean of 22.5 by 16.5 microns.

The young oocysts differed from the mature macrogametes in which the palastic granules of the latter coalesced to form the oocyst wall (Figure 7). The young oocysts in the sections were 19 to 24 by 11 to 20 microns in diameter with a mean of 21.5 by 18.5 microns in diameter.

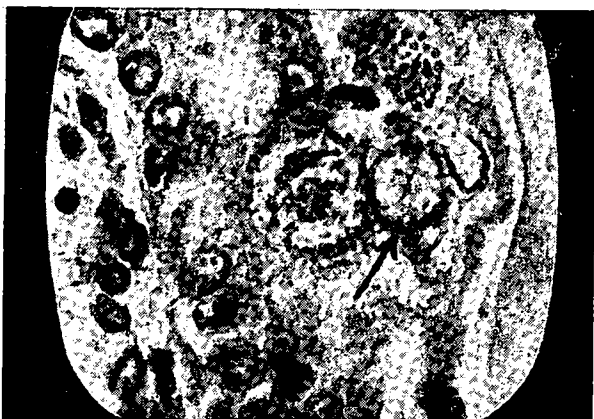
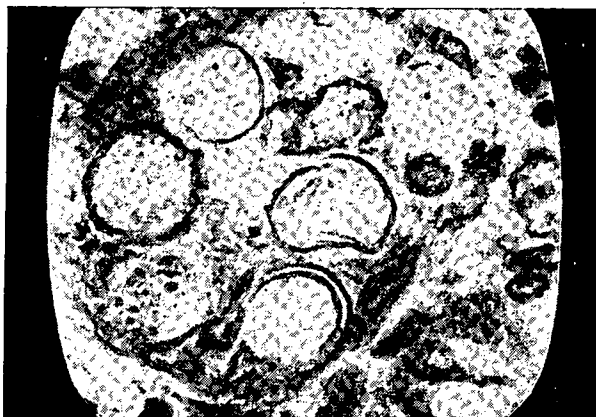
Figure 6. microgametocyte of *Eimeria nina-kohl-yakimovi*.



Şekil 7. young oocysts of *Eimeria nina-kohl-yakimovi* in tissue.

### Discussion

The question may arise as to which species of *Eimeria* the endogenous stage belongs. Although the kid passed out the pure oocysts of *Eimeria nina-kohl-yakomavi*, this does not necessarily mean that the stage of *Eimeria* belongs to that species. The schizonts, microgametocytes and oocysts do not resemble both in morphology and in location those described by Lotze<sup>13</sup> for *Eimeria arloingi* in sheep and by Levine et al<sup>12</sup> for *Eimeria arloingi* in goats. The

schizonts were not similar, either, to the giant schizonts which have been reported for *Eimeria nina-kohl-yakimovi* <sup>14</sup>, *Eimeria parva* in sheep <sup>10</sup> and in Angora goats <sup>17</sup>. They also differ in their sizes from the small schizonts from sheep <sup>10</sup> and Angora goats <sup>17</sup>. The schizonts from goats were described by Balozet <sup>2</sup> for *Eimeria nina kohl-yakimovi*. These measured 15 to 35 microns. Each nuclei in them was separated by a clear zone from the cytoplasm. The schizonts from the kid in this study resemble these. The microgametocytes found in the present sections were also similar with respect to their sizes and positions of their nuclei to those described by Balozet <sup>2</sup> from kids. The mature macrogametes and young oocysts carrying micropolar cap described by Balozet <sup>2</sup> for *Eimeria nina-kohl-yakimovi* from kids were not present in the Angora kid examined in this study. The macrogametes in our sections resemble both in morphology and location those mentioned by Lotze <sup>14</sup> for *Eimeria nina-kohl-yakimovi*.

### S u m m a r y

Oocysts of *Eimeria nina-kohl-yakimovi* were found in the feces of an Angora kid, with lesions of coccidiosis in the small intestine. The oocyst is described in detail. They were round, rarely short-oval, and measured 21 to 28 by 18 to 24 microns and contained oval round or egg shape sporocysts measuring 4 to 12 by 4 to 7 microns. The oocysts of this species were found in the feces of 207 (23 %) out of 900 Angora goats.

Endogenous stages in the small intestine, cecum and upper colon included schizonts, merozoites, macrogametes, microgametocytes and oocyst in the epithelial cells. These are also described in detail.

### Ö z e t

Tiftik keçilerinde *Eimeria parva*'nın patojenitesi ve biyolojisini incelemek üzere satın alınan deneme oğlaklarından birinde tabii coccidiosis zühur etmiştir. Oğlakta görülen hafif bir ishal'i müteakip yapılan gaita muayenesinde bol miktarda saf *Eimeria nina-kohl-yakimovi* oocystleri tesbit edilmiştir. Mevcut literatürlere göre Ankara keçilerinde bu türün asxual ve sexual gelişme devirleri incelenmemiştir. Bu hususları etüt etmek maksediyle oğlak öldürülmüş ve üzerinde gereken muayeneler yapılmıştır.

Gaitada görülen oocystler yuvarlak veya oval, çift cidarlıdır. Mikropil ve kep yoktur. 21-28 mikron uzunlukta, 18-24 mikron genişliktedir. Oocyst protoplasma bakiyesi yoktur. Sporocyst'ler ovaldır. 4-12 mikron uzunlukta ve 4-7 mikron genişliktedir. Sporocyst protoplasma bakiyesi vardır. Ankara ve civarında yapılan sürveyde 900 ankaralı keçisinden 207 (% 23) sinin gaitasında bu türün oocystlerine rastlanmıştır.

Öldürülen oğlağın ince barsak ve sekum makozasında yaygın ve toplu iğne başı cesametinde, küçük, beyazımsı derenler görülmüştür. Barsak da herhangi bir kanamaya rastlanmamıştır. Sadece mukozada kalınlaşma tesbit edilmiştir.

Barsak mukozasından yapılan taze frotilerde merozoite'ler görülmüş ve ebatları ortalama 11x11 mikron olarak tesbit edilmiştir. Schizont'lara ince barsak, kalın barsak ve sekum'dan yapılan kesitlerde rastlanmıştır. Schizont'lar bilhassa epitel hücreleri içinde görülmüş, uzunlukları 31-43, genişlikleri 22-31 mikron olarak bulunmuştur. Barsak mukozasının epitel hücrelerinde, schizont'ların görüldüğü yerlerde macrogamete, microgametocyte, genç oocyst'ler de tesbit edilmiştir.

## R e f e r e n c e s

1. **Antipin, D. N.; V. S. Ershow; N. A. Zolotarev and V. A. Salyaev** (1956): *Parasitology and Parasitic diseases of Livestock* State publishing House for Agriculture literature, Moscow.
2. **Balozet, T.** (1932): *Les coccidies du mouton et de la chèvre. Cycle evelotive de E. nina-kohl-yakimovi Yakimof et Rastegaive, 1930.* Archives de l' Institut Pasteur de Tunus **xxi**, 1. 88-118.
3. **Becker, E. R.** (1934): *Coccidia and coccidiosis of domesticated game, laboratory animals and of man.* Collegiate Press Inc. Iowa, America.
4. **Becklund, W. W.** (1957): *An epizootic of coccidiosis in western feeder lambs in Georgia.* North Amer. Vet. **38**, 262-264.
5. **Christensen, J. F.** (1938): *Species differentiation in the coccidia from the domestic sheep.* J. Parasitol. **24**, 5, 453-468.
6. **Davis, L. R.; G. W. Bowman; W. N. Smith** (1963): *Observation on the endogenous cycle of Eimeria ahsata Honess, 1942 in domestic sheep.* J. Parasitol. **10**: supplement, 8.
7. **Davies, S. F. M.; L.P. Joyner and S. B. Kendall** (1963): *Coccidiosis.* Oliver and Boyd, Edingburg.



8. **Deom, J.; J. Mortellmans** (1956): *Observation sur la coccidiosise du mouton et de la chèvre au Congo Belge*. Ann. Soc. Belge. Med. Trop. 36: 47-57.
9. **Foster, A. O.** (1949): *The economic losses due to coccidiosis*. Ann. N. Y. Acad. Sci. 52, 468-472.
10. **Kotlan, A.; L. Pellerdy und L. Versenyi** (1951): *Experimentelle studien über die kokzidiose der schafe, I. die endogene entwicklung von E. parva*. Acad. Vet. Budapest. V. 1 (3) 317-331.
11. **Levine, N. D.** (1961): *Protozoon parasites of domestic animals and of man*. Burgess Publishing Company.
12. **Levine, N. D.; V. İvens, and T. E. Frits**, (1962): *Eimeria christensini sp. n. and other coccidia of goat*. J. Parasitol. 48, 2. 255-269.
13. **Lotze, J. C.** (1953): *Life history of the coccidian parasite, Eimeria arloingi, in domestic sheep*, J. Amer. Vet. Res. XIV, 50, 86-95.
14. **Lotze, J. C.** (1953): *The patogenicity of the coccidian parasite E. ninakohlyakimovi in domestic sheep*. Amer. Vet. Med. Ass. ninetienth Ann. Meeting (proceeding book) 141-146.
15. **Melikyan, E. L.** (1955): *Coccidiosis of sheep and goats in the Armenian S. S. R.*, Trud Armeniyan Nauchno-İssled Vet. Inst. 8: 83-91.
16. **Merdivenci, A.** (1959): *Evcil koyun ve keçilerimizde coccidia nevi-leri ve bazı deneyler*. Türk. Vet. Hek. Der. Dergisi. 20: 260-281.
17. **Sayın, F.** (1964): *Tiftik keçilerinde bulunan Eimeria türleri. E. parva'nın biyolojisi üzerinde deneysel arařtırmalar*. Tez, A. Veteriner Fakültesi. Henüz basılmamıřtır.
18. **Shumard, B. F.** (1957): *Studies on ovine coccidiosis. Some physiological changes taking place in experimental infections with E. ninakohl-yakomivi and E. faurei*. J. paristol. v, 43, 5. 548-554.
19. **Smith, W. N.; L. R. Davis** (1960): *The life cyle of Eimeria ahsata*. J. protozool. 7 (suppl.) 8.
20. **Svanbaev, S. K.** (1957): *K Voprosu o fauna i morfoloji koktsidii ovetsi koz zapodnogo kazakhstane*, Trudy Instituta zoologii Akad. Nauk Kazakh S. S. R. Tom, VII, 252-257.
21. **Yakimof, W. L.** (1933): *La coccidiose des animaux domestiques dans l'Azerbaidjan*. Ann. Soc. Bel. Med. Trop. 13, 93-130.

Received 20 Feb. 1965