

Case Report / Olgu Sunumu

A case of Cheilognathopalatoschisis in a simmental breed calf: A rare case

Ali Said DURMUŞ^{1,a}, Eren POLAT^{1,b,✉}

¹Firat University, Faculty of Veterinary Medicine, Department of Surgery, Elazig, Turkey

^aORCID: 0000-0003-4873-5690; ^bORCID: 0000-0002-3999-1310.

✉Corresponding author: erenpolat@firat.edu.tr

Received date: 11.06.2021 - Accepted date: 28.02.2022

Abstract: The subject of this study was a 7-day-old female Simmental calf brought to Firat University Veterinary Faculty Animal Hospital Surgery Clinic with the complaint of cleft in the upper lip and palate. In the clinical examination, it was determined that the calf had respiratory difficulties and the nostrils were not formed normally. The calf was diagnosed with cheilognathopalatoschisis. Palatoplasty and reconstructive surgery were performed on the calf for the treatment of the rarely encountered case. The mucosa of the cleft hard palate was freed by dissecting from the os palatinum on both sides. Then, the hard palate was repaired by suturing the mucosal edges mutually. Palatal and alveolar clefts were repaired using Veau's technique. During the post-operative interview with the patient's owner, it was learned that the calf had difficulty in swallowing during feeding. It was determined that the calf died on the 8th postoperative day due to aspiration pneumonia that developed due to the absence of probable swallowing reflex.

Keywords: Anomaly, calf, cheilognathopalatoschisis, congenital, simmental.

Simental ırkı bir buzağıda Şilognatopalatoşizi olgusu: Nadir bir olgu

Özet: Bu çalışmanın konusunu, üst dudak ve damağında yarık şikâyeti ile Firat Üniversitesi Veteriner Fakültesi Hayvan Hastanesi Cerrahi Kliniği'ne getirilen 7 günlük, dişi simental ırkı bir buzağı (7 günlük yaşta, dişi) oluşturdu. Yapılan klinik muayenede, buzağının solunum güçlüğünün olduğu ve burun deliklerinin normal olarak şekillenmediği tespit edildi. Buzağıya cheilognathopalatoschisis teşhisi konuldu. Nadiren karşılaşılan olgunun tedavisi için buzağıya palatoplasti ve rekonstrüktif cerrahi uygulandı. Yarık olan sert damağın mukozası her iki tarafta os palatinumdan diseke edilerek serbest hale getirildi. Daha sonra mukozal kenarlar karşılıklı olarak dikilerek sert damak onarıldı. Damak ve alveoler yarıklar ise Veau's tekniği ile karşı karşıya getirilerek onarıldı. Postoperatif dönemde hasta sahibi ile yapılan görüşmede buzağının beslenme sırasında yutma zorluğu yaşadığı öğrenildi. Postoperatif 8. gün buzağının olası yutma refleksinin oluşmamasından dolayı gelişen aspirasyon pnömonisi sebebiyle öldüğü belirlendi.

Anahtar sözcükler: Anomali, buzağı, şilognatopalatoşizi, konjenital, simental.

Cheilognathopalatoschisis is the simultaneous cleft of the upper lip, maxilla, and upper palate in newborns. Although it is one of the most common congenital anomalies especially in humans, it is rarely encountered in animals (9). Cheilognathopalatoschisis, also known as rabbit-lipped, is an inherited defect with multifactorial genetic predisposition. Although it is hereditary, environmental stimuli are quite important in the etiology of the disease (2, 7, 9, 14). Exposure of cattle during pregnancy to piperidine alkaloids, some poisonings (with

wild tobacco (*Nicotiana glauca*), selenium and lupine species) and some viral diseases (Cache Valley virus, Akabane virus, Aino and Chuzan viruses, and bovine viral diarrhea (BVD) virus) may cause congenital cleft palate and cheliognatopalatoschisis (14).

Cleft palate is classified in different ways according to the presence, location and type of cleft. Some of these classifications are Davis and Ritchie's classification, Veau's classification, Kernahan and Stark's classification and LAHSAL classification. The LAHSAL classification

is an assessment method developed by Kriens in 1989 and accepted by the Royal College of Surgeons in 2005. The abbreviation that was LAHSHAL when Kriens developed it has been used as LAHSAL recently. The abbreviation LAHSAL consists of letters representing the six regions of the mouth. Accordingly, L=right lip, A=right alveoli, H=hard palate, S=soft palate, A=left palate, L=left lip (Figure 1). In the LAHSAL code, capital letters indicate complete cleft formation, and small letters indicate incomplete clefts. The dot mark indicates that the anatomical structure is formed normally (5, 10, 13).

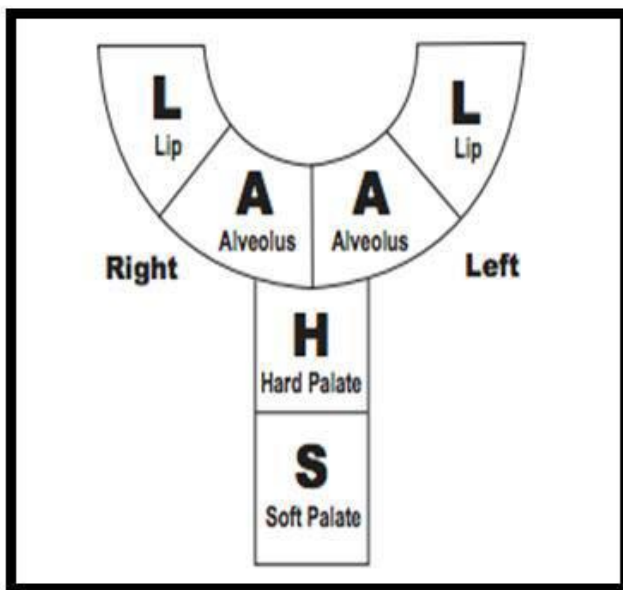


Figure 1. LAHSAL classification.

In cheliognatopalatoschisis cases, due to the connection between the mouth and nasal cavity, ingested food and water may escape into the lungs and cause aspiration pneumonia. This situation thought to be a simple structural disorder, can cause complications that cause the death of the patient (4, 6, 12). Palatoplasty and some reconstructive surgery techniques (such as Millard's technique, Tennison-Randall's technique and Veau technique) can be used to treat cheliognatopalatoschisis cases (1, 4, 6, 11-13, 15). Millard's and Tennison-Randall's techniques are mostly used in unilateral cleft lip (1, 11, 13). The Veau technique is a reconstructive surgical technique that is used more often in bilateral cleft lip, in which the cleft line is repaired in a straight way (13, 15). In this study, the diagnosis, treatment and results of a case of cheliognatopalatoschisis in a Simmental calf were shared.

In this study, a simmental calf (7 days old, female) brought with the complaint of cleft in the upper lip and palate was the subject. In the anamnesis, it was learned that the calf had respiratory difficulties and coughed during food intake. In the clinical examination, it was determined that the right and left nostrils of the calf were not fully formed (Figure 2a). In addition, a wide cleft in the cranial half of the palatum durum was detected (Figure 2b, 2c). It was determined that the calf had respiratory distress. After the examination, the patient was diagnosed with cheliognatopalatoschisis (rabbit lipped). When the diagnosis of the patient was evaluated according to the LAHSAL classification, it was determined that it had LAh.AL type cleft palate and lip (Figure 2).

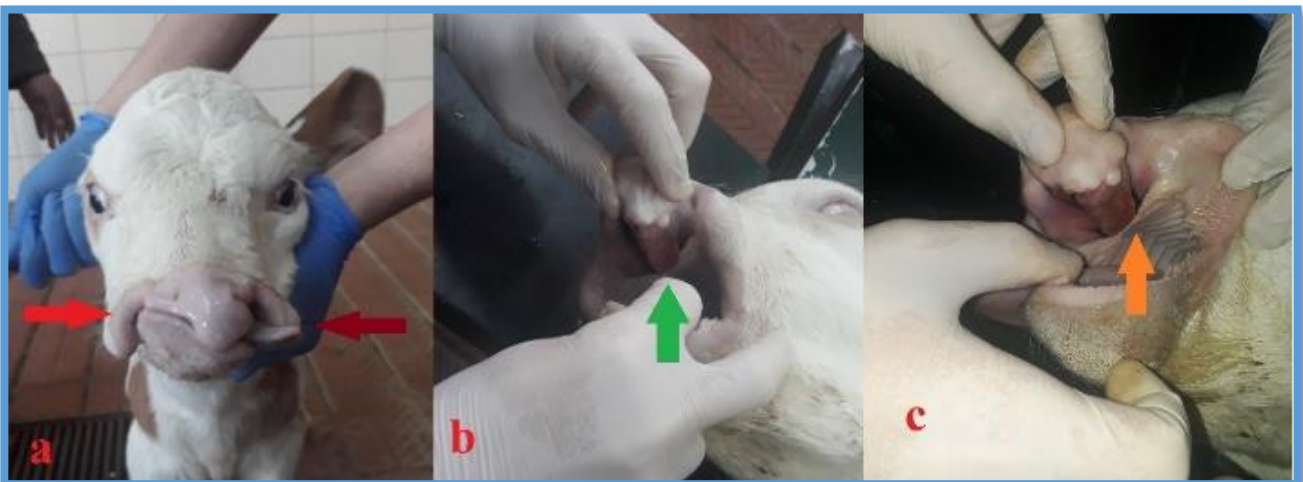


Figure 2. Abnormal position of the nostrils (a), cleft of the hard palate (b, c).

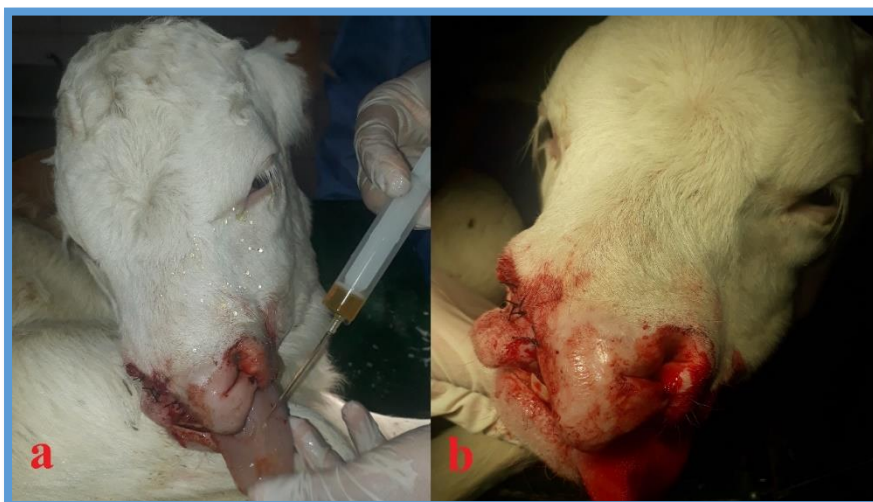

Figure 3. The patient's nostrils in their normal position after the operation (a, b).

It was decided to perform palatoplasty and reconstructive surgery in order to prevent aspiration pneumonia and correct the structural malformation. Before the operation, sedation was provided by intramuscular administration of 0.1 mg / kg dose of xylazine hydrochloride (*Xylazinbio*[®] %2, *Bioveta, Czech Republic*). After ten minutes, anesthesia was provided by intramuscular administration of ketamine hydrochloride (*Ketasol*[®] %10, *Richterpharma, Austria*) at a dose of 4 mg/kg. After the calf was anesthetized, the hard palate mucosa was freed by dissection from the os palatinum. Then, the free mucous membranes were brought face to face and sutured with non-absorbable suture material. It was then decided to perform reconstructive surgery to create the medial wing of the nose. For this, the bilateral lip and alveolar cleft were repaired by suturing them in a straight line using the Veau technique. For this, a 0.5 cm diameter wound line was created in the medial ends of the upper lips and the philtrum region. The wound lines created on the upper lips were stitched opposite the wound lines in the philtrum region, and the region was optimized for its normal anatomical structure. Stitches were applied using non-absorbable threads (Figure 3). Amoxicillin-clavunic acid (*Synulox, Zoetis, Latina, Italy*) was administered intramuscularly at a dose of 8.75 mg/kg for five days postoperatively. For postoperative pain management, 0.5 mg/kg of meloxicam (*Bavet Meloksikam, BaVET, Istanbul, Turkey*) was administered in two doses, once every three days. In addition, oral feeding of the animal was prevented for 3 days in the postoperative period, and 5% dextrose (*Dekstro-Flex, Eczacıbaşı-Baxter, Turkey*) solution was given intravenously. In the postoperative period, it was reported that the calf died on the 8th day in the interview with the patient's owner. The owner of the patient reported that the calf's breathing and swallowing difficulties continued during the post-operative period when oral feeding was started. According to information obtained from the

patient's owner, it was suspected that the patient died due to aspiration pneumonia that developed due to the failure of the swallowing reflex.

Although congenital cleft palate and cheliognatopalatoschisis are hereditary defects, environmental stimuli are very important in their occurrence (2, 7, 9, 14). Exposure to piperidine alkaloids, some poisonings (wild tobacco (*Nicotiana glauca*), selenium and lupine) and viral diseases (Cache Valley virus, Akabane virus, Aino virus, Chuzan virus, and Bovine Viral Diarrhea virus) during pregnancy are the most important environmental factors for the occurrence of these cases (14). In this case report, it was determined that astragalus was grown intensively in the region where the calf with cheliognatopalatoschisis lived. Selenium accumulates at a high level in the Astragalus plant (16). The reason for the formation of this anomaly is thought to be caused by the mother's consumption of Astragalus during pregnancy. It is thought that selenium toxicity caused by sodium selenite, which is used for protective purposes in the last third of pregnancy, may also cause this anomaly.

Congenital cleft palate can be seen with acroteriasis syndrome in Holstein, chondrodysplasia in Dexter, arthrogryposis and spinal anomalies in Charolais, hydrocephalus, diaphragmatic hernia and freemartins in Simmental cattle (8, 14). In this case, necropsy could not be performed because the owner did not give permission. In the clinical examination, no other anomaly was found in the calf, which was diagnosed with cheliognatopalatoschisis.

Cleft palate and lip clefts are classified by different methods according to their presence, location and type. The most used methods are Veau's technique and LAHSAL technique. The LAHSAL technique was developed by Kriens in 1989. Each letter in the LAHSAL abbreviation represents the anatomical regions of the mouth. (L= right lip, A=right alveoli, H=hard palate,

S=soft palate, A=left alveol, L=left lip). In these anatomical formations, if there is a complete cleft, it is indicated with a capital letter, if there is an incomplete cleft, it is indicated with a small letter (4, 10, 13). In this case report, it was determined that the calf diagnosed with cheliognatopalatoschisis had LAh.AL type palate and lip cleft according to the LAHSAL technique.

Aspiration pneumonia is one of the most common complications in calves with congenital cleft palate and cheliognathopalatoschisis (4, 6, 12). Smolec et al. (12), reported that frequent coughing and dripping milk from the nostrils in a 21-day-old Simmental calf with congenital cleft palate. Although palatoplasty was performed to restore palate integrity, it was decided to euthanize the calf due to aspiration pneumonia that developed in the second postoperative week (12). In this study, as in the study of Smolec et al. (12), it was determined that the calf died due to aspiration pneumonia in the first postoperative week, despite palatoplasty and reconstructive surgery.

The type and width of the clefts are very important when determining the treatment method of cleft palate and lip (3, 4, 6, 12, 13). If the cleft palate is not too wide, it can be closed with a cerclage wire. In some cases, cleft palate can be treated by applying methyl methacrylate, cold acrylic and propylene mesh locally. If the defects are large in cleft palate, autograft skin or fascia graft can be applied (3, 4, 6, 12). In this study, since the cleft in the hard palate was not wide, the hard palate mucosa was freed by dissection from the os palatinum. Then, the free mucous membranes were brought face to face and sutured with non-absorbable suture material. In the treatment of lip and alveolar clefts, it is very important whether the clefts are unilateral or bilateral. While Millard's technique or Tennison-Randall's technique is applied mostly in unilateral clefts, Veau technique is applied in bilateral clefts (1, 11, 13, 15). In this study, the lips were sutured to the philtrum region in a simple straight line by applying the Veau technique in a calf with bilateral lip and alveolar clefts.

In conclusion, cheliognatopalatoschisis is an anomaly that can have fatal complications and can be seen in all animal species. The most important and fatal complication is asphyxia due to aspiration pneumonia. This study revealed that the classification of cleft palate and lip is very important in determining the treatment method and possible complications. This study contributes to the literature on the management of the operative and postoperative process in similar cases.

Financial Support

This research received no grant from any funding agency/sector.

Ethical Statement

This study does not present any ethical concerns.

Conflict of Interest

The authors declared that there is no conflict of interest.

References

1. **Adetayo AM, James O, Adeyemo WL, et al** (2018): *Unilateral cleft lip repair: A comparison of treatment outcome with two surgical techniques using quantitative (anthropometry) assessment*. J Korean Assoc Oral Maxillofac Surg, **44**, 3-11.
2. **Aksoy Ö, Kılıç E, Öztürk S, et al** (2004): *Bir buzağıda median yüz yarığı anomalisi*. Kafkas Üniv Vet Fak Derg, **10**, 109-111.
3. **Arıcan M** (2017): *Sığır Cerrahi Atlası*. Damla Ofset AŞ, Konya.
4. **Canatan U, Şen MM, Özfırat E, et al** (2020): *Palatoschisis, brachygnathia inferior and accessory mandibular mass in a Simmental breed calf*. Large Animal Review, **26**, 145-148.
5. **Cetin E** (2017): *Dudak ve damak yarığı deformiteli hastaların ortodontik kayıtlarına ait demografik verilerin incelenmesi*. Hacettepe Üniversitesi Diş Hekimliği Fakültesi Ortodonti Anabilim Dalı, Uzmanlık Tezi.
6. **Conze T, Ritz I, Hospes R, et al.** (2018): *Management of cleft palate in puppies using a temporary prosthesis: a report of three cases*. Vet Sci, **61**, 1-7.
7. **Di Muro G, Cagnotti G, Bellino C, et al** (2020): *Multiple cephalic malformations in a calf*. Animals, **1532**, 1-9.
8. **Headrick JF, McAnulty JF** (2004): *Reconstruction of a bilateral hypoplastic soft palate in a cat*. J Am Anim Hosp Assoc, **40**, 86-90.
9. **Malek FA, Bienengraber V, Paul I, et al** (1999): *Cheilognathopalatoschisis and its prophylaxis in animal experiments*. Ann Anat, **181**, 107-110.
10. **McBride WA, McIntyre GT, Carroll K, et al** (2016): *Subphenotyping and classification of orofacial clefts: need for orofacial cleft subphenotyping calls for revised classification*. The Cleft Palate–Craniofacial Journal, **53**, 539–549.
11. **Millard DR** (1964): *A primary camouflage in the unilateral harelip*. In: Skoog T, editor. Trans 1st International Congress Plastic Surgery. Baltimore:Williams & Wilkins, 160.
12. **Smolec O, Vnuk D, Kos J, et al** (2010): *Repair of cleft palate in a calf using polypropylene mesh and palatal mucosal flap: a case report*. Veterinarni Medicina, **55**, 566–570.
13. **Subramanyam D** (2020): *An Insight of the Cleft Lip and Palate in Pediatric Dentistry - A Review*. J Dent Oral Biol, **5**, 1-6.
14. **Usta Z, Distl O** (2017): *Congenital cleft lip-jaw-palate and cleft palate in german holstein calves with common ancestry*. Erciyes Üniv Vet Fak Derg, **14**, 73-80.
15. **Veau V** (1922): *Operative treatment of complete double harelip*. Ann Surg, **76**, 143-56.
16. **Yavas I, Cınar VM, Unay A** (2020): *Bitkilerde abiyotik stres koşullarında selenyum metabolizması ve fizyolojik etkileri*. EJOSAT, **18**, 840-849.