

The use of plastinated specimens for hybrid education of Veterinary Anatomy

Okan EKİM^{1,a,✉}, Caner BAKICI^{1,b}, Barış BATUR^{1,2,c}, Selçuk TUNALI^{3,d}

¹Ankara University, Faculty of Veterinary Medicine, Department of Anatomy, Ankara, Türkiye; ²Ankara University, Graduate School of Health Sciences, Ankara, Türkiye; ³TOBB University of Economics and Technology, Faculty of Medicine, Department of Anatomy, Ankara, Türkiye

^aORCID: 0000-0002-3322-4161; ^bORCID: 0000-0003-2413-3142; ^cORCID: 0000-0001-9669-9917; ^dORCID: 0000-0003-3553-7660

ARTICLE INFO

Article History

Received : 10.07.2022

Accepted : 13.09.2023

DOI: 10.33988/auvfd.1142921

Keywords

Anatomy

Earthquake

Education

Hybrid learning

Plastination

✉Corresponding author

okanekim@yahoo.com

How to cite this article: Ekim O, Bakıcı C, Batur B, Tunali S (2024): The use of plastinated specimens for hybrid education of Veterinary Anatomy. Ankara Univ Vet Fak Derg, 71 (1), 109-116. DOI: 10.33988/auvfd.1142921.

ABSTRACT

With the official announcement of the new type of coronavirus-induced COVID-19 outbreak as a global pandemic, an extraordinary situation that no one has ever encountered has started. Just as life was about to return to normal in Türkiye, two devastating earthquakes, centered in Kahramanmaraş, affected ten different cities. Many global and national developments in various fields, which are expected to happen in the distant future, were completed within 3 years. One of these fields was undoubtedly education. Hybrid learning is seen as a trending educational approach combining face-to-face and online learning. Plastinated specimens come to the forefront for hybrid education with various advantageous features. They are not only non-toxic, dry, odorless materials, but also can simulate the natural anatomic appearance in detailed manner. With the help of new-generation acrylic paints and dyes which can penetrate into tissues, plastinates offer a unique natural look rather impressive than any other techniques. Due to the features mentioned above, plastinates are also convenient materials for handling, transportation or storage. These issues will be discussed in our article in terms of compatibility with hybrid learning. The aim of this article is to give ideas and make suggestions about how plastinates, which have been used efficiently in anatomy practices and professional training, can be used in hybrid veterinary anatomy education.

Introduction

On January 30, 2020, with the World Health Organization's (World Health Organization / WHO) official announcement of the new type of coronavirus-induced COVID-19 outbreak and then declaring it as a global pandemic, an extraordinary situation that no one has ever encountered in the world before has started. And subsequent measures-restrictions quickly entered people's lives (12, 16, 21, 31). While countries were searching for solutions to this pandemic by using their own scientific and administrative resources, various regulations and protocols were put into effect in a short time (16, 17).

Improvements and updates that are expected to happen in the next 10 years in many fields such as technology, communication, economy, health and so on have been completed in the last 3 years. One of these fields was undoubtedly education. On March 11, 2020, face-to-

face education was completely stopped in Türkiye. At the first months of Covid-19 outbreak, in order to ensure the continuity of education in the current education systems in the world and in Türkiye, emergency remote education implementations had been started quickly and imperatively before the distance education. This happened because of the inexperience of the whole world in this extraordinary situation (4, 8, 10). Afterwards, all schools, including universities, continued to interact with their students through distance education methods, digital content and e-learning materials for more than a year. After the total lockdown, educational institutions started to reopen gradually. On-line and in-class (face-to-face) education with reduced student groups were initially implemented together. Finally, the classrooms were meeting with the students again (4, 8, 10, 20, 37). While daily life in our country would start to return to the pre-

pandemic period, two devastating earthquakes occurred nine hours apart and caused severe destruction in 10 different cities. Shortly after the pandemic, unfortunately, the state of emergency regulations and restrictions started again in Türkiye (41).

Although the COVID-19 infection is no longer a deadly pandemic, do you think the danger has passed completely? Unfortunately, the Critical Disease Control Center (CDC), the World Health Organization (WHO) and many other global health organizations are discussing the same issue on these days: When will be the next pandemic? Many health authorities believe that a new pandemic will, unfortunately, threaten humanity again in the near future. This threat can originate from biological terrorism, or it can start with a simple virus hiding in a jungle and ready to mutate. If an unexpected global pandemic occurs, is the world ready for this war in all fields (5, 19)?

During the total lockdown, the efficiency of the education offered to undergraduates at various universities decreased undeniably. Veterinary faculties were among the institutions most affected by the negative effects of distance education, as they included intensive practical courses and clinical training. Because no one was experienced enough in this matter. Neither trainers nor learners... This unfortunate global pandemic triggered improvements in educational methods, fortunately. Although these alternative education methods have been around for some time now, they have gained traction in the last 3 years.

Even though the pandemic seems to reach a plateau and efforts to reduce the negative effects of the earthquake are at a good stage, learners as well as educators gained lots of experience on distance education and some of these new techniques may be preferred whether there is a need or not in the future (20, 26, 27, 37).

Hybrid learning is a trending educational approach that combines face-to-face and on-line learning. Some of the learners attend the class in person, while others join virtually and remotely through hybrid learning. Trainers and lecturers utilize various tools such as video conferencing or electronic learning materials for the optimum education of both of these student groups in hybrid education. Hybrid education can entail some online exercises, e-learning materials, videos, and other materials that will also support in-person classes. Not only for the official lectures but also to create extracurricular learning activities, hybrid education seems to be a convenient alternative for the teaching of veterinary anatomy (15, 34). However, for hybrid education to be useful and effective, appropriate learning tools, facilities and materials must be used.

Can plastinated materials be efficient tools to implement these updated learning methods for veterinary

anatomy education? The purpose of this review is to give ideas and make suggestions about how plastinates, which have been used efficiently in anatomy practices and professional training, can be used in on-line courses or hybrid education.

Although the plastination was first discovered by Dr. Gunter von Hagens in the early 1970s, it is still one of the most up-to-date anatomical techniques with new modifications. In 1986, the pioneers in plastination established the International Society for Plastination and only after one year the Journal of the International Society for Plastination has published the first issue. On the other hand, von Hagens followed a bit fancy way to improve and get the plastination around the world. He established The Institute for Plastination, an alternative organization at Heidelberg in 1993. And immediately after that, von Hagens designed the most extraordinary exhibition, Body Worlds, in 1995 (18, 30). Thus, this idea, which was initially put forward to support anatomy students who are trying to complete their doctoral thesis, has turned into a tool used in anatomical and clinical education and a method to prepare popular and impressive exhibitions visited all over the world in recent years. Although this technique is still a matter of ethical and moral debate for various scientific groups, and even though some articles go even further and call the exhibitions "freak show", plastination has become an integral part of anatomy education (9, 33, 38).

Plastination Techniques Applied Worldwide

Briefly, plastination is a technique performed by replacing body fluids in tissues and organs with a reactive curable polymer at appropriate pressure and temperature. Essential but hazardous hydrophilic intermediary solvents, mostly acetone or alcohol, are used while the tissue fluids are replaced with the polymer. Three standardized plastination techniques have generally been used in plastination laboratories around the world (Figure 1) (13, 14, 18).

Silicone Plastination: It is the most widely used and basic method worldwide, in which the whole body, body parts, organs or tissues are plastinated through a reactive silicone polymer. Silicone plastination is an ideal method for beginners and newly established laboratories due to its relatively easy application compared to other plastination techniques (13, 35).

Epoxy Plastination: Epoxy plastination produces 2-8 mm thickness of semi-transparent plastinates by using epoxy resins. In this technique, all tissue fluids and a significant amount of adipose tissue are replaced with a curable epoxy resin mixture. In these cross-sections, anatomical structures can be examined with naked eye in a commendable quality down to a submacroscopic level (35, 36).

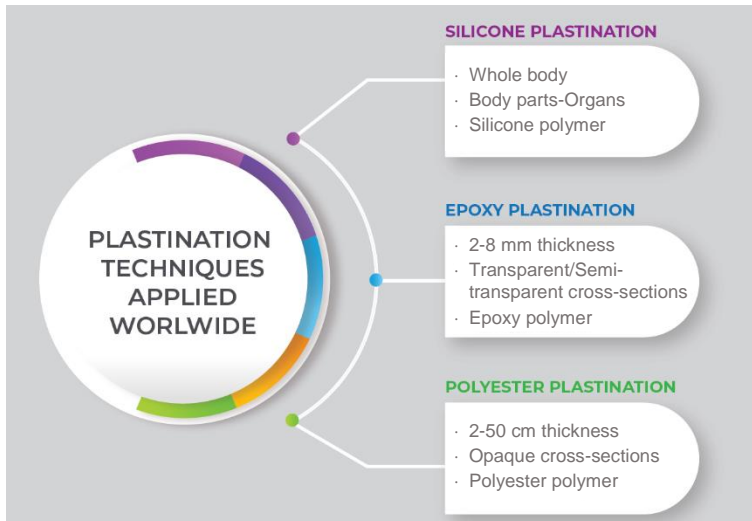


Figure 1. Standardized plastination techniques that have been used in plastination laboratories around the world.

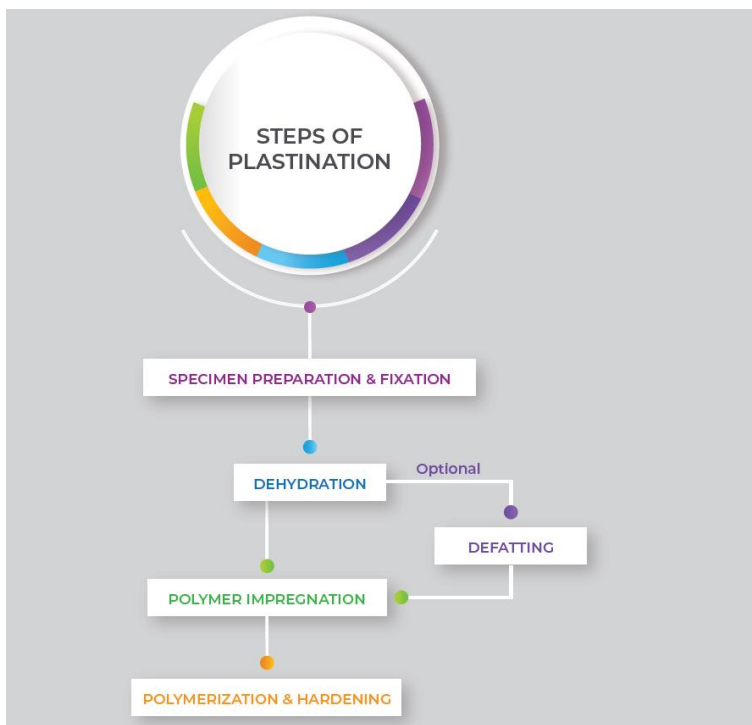


Figure 2. Five consecutive steps that are used for silicone, epoxy and polyester plastination procedures.

Polyester Plastination: Polyester plastination produces, body or organ slices, especially brain cross-sections, with 2 mm to 5 cm thickness. The tissue fluids are removed and replaced with a curable polyester resin in this method. While epoxy plastination produces transparent sections, specimens prepared with polyester plastination are opaque plastinates. Because, a considerable amount of adipose tissue is removed by acetone or methylene chloride (1, 2, 39).

Steps of Plastination Procedure

Five common steps can be described for the general procedure of plastination: Specimen preparation and fixation, dehydration, defatting, forced impregnation, polymerization and hardening (Figure 2).

Specimen Preparation and Fixation: Early preparation of the biological tissues by minor or gross dissections has been the most important part of the plastination process, because the final appearance of the plastinates are formed by the meticulous application of this very first step (11, 18).

Dehydration: Dehydration (or freeze substitution) is the main stage that tissue fluids are replaced with an organic solvent. This solvent must be hydrophilic and volatile enough as an intermediary chemical which is the key for the next step. The most convenient solvent is acetone for this step. Prepared and fixated specimens should be kept in pure acetone baths in order to eliminate all unnecessary fluids (7).

Defatting (Degreasing): Excess lipids in the tissue or extraordinary fatty specimens can affect the final quality of plastinates and should be removed if possible. Defatting is the removal of excess fat from the specimen. Although the procedure is quite similar to those in the dehydration stage, the main difference is the acetone bath should be performed at room temperature in order to eliminate excess fat (7).

Forced (Polymer) Impregnation: This stage is the replacement of volatile organic solvent in the specimen with curable silicone, epoxy or polyester polymer at a specified temperature and negative pressure. These polymers are quite viscous to come to equilibrium with the intermediary solvent. Thus, a negative pressure (vacuum) is needed to get the polymer inside the specimen. This special application gives the name “forced impregnation” to this step (7, 13).

Polymerization and Hardening: Polymerization and finally hardening of the specimen is the last stage for a specimen fully loaded with polymer. Chain extension and cross-linkage of polymer molecules to provide longer chains and to form a firm 3D meshwork respectively is the basic principle for this stage. This polymerization activity can be formed by exposing the specimen to a curable gaseous hardening chemical or an ultraviolet-A light with a specified wavelength or regulated temperature (7, 23, 36).

Advantages & Disadvantages of Plastination for Anatomy Education

All organic specimens, even macerated bones, have an estimated useful life. Although you preserve your samples in the best manner, decomposition eventually occurs on the tissues and the specimen becomes out of use and discarded in a proper way. When compared with the alternative anatomic specimens, plastinates are distinguished with their very durable structures. Besides, plastinates are easy to keep and use for various courses and practices. Once you manage to plastinate and preserve your specimen in a very optimum way, it can be everlasting. This word may come as “exaggerated” to the readers. However, the first samples which had been prepared by von Hagens in early 70’s are still in use (13, 33).

Different kinds of toxic or hazardous chemicals are used for the various stages of plastination. Formalin is almost an essential solution for the proper preparation of specimens in the first step. On the other hand, removing all formalin from the specimen is also essential for the next step. Again acetone, a toxic and very explosive chemical, is an irreplaceable chemical for the dehydration stage of plastination. However, this intermediary volatile solvent is

totally removed in the next step. Therefore, specimens transform into biosafe and non-toxic plastinates at the end of the plastination procedure. And this makes plastination privileged among the various anatomic techniques (11, 40).

Final products are not only non-toxic, dry, odorless materials. A well-prepared plastinate can simulate the natural anatomic appearance in a detailed manner. With the help of new-generation acrylic paints and water-based dyes which can penetrate into tissues, plastinates offer a unique natural look rather impressive than any other techniques. Due to the features mentioned above, plastinates are also convenient materials for handling, transportation or storage (30, 40).

Beside the remarkable advantages of plastination, some disadvantages should be considered. The leading problem that should be mentioned is the financial cost. The initial investment cost for a plastination lab can be rather high. However, the maintenance of the lab and the plastination procedures will be much more manageable after setting up the lab. The unit cost of the plastinates will decrease day by day (40).

At that point, the most important situation that should be noticed by the staff is the laboratory safety rules. Some of the essential chemicals which are used during the plastination procedure can be corrosive or explosive. And the laboratory personnel should know the regulations before taking the first step to the plastination lab (18, 29, 40).

As mentioned at the beginning of the article, ethical concerns are still a serious matter of debate, especially for the human-origin specimens (9, 38). However, it seems to be a surmountable issue for the veterinary medicine field. With the proper ethical legislations and professional regulations, which have been in service in European countries, the plastination technique has been applied in veterinary institutes for many years.

Plastination for Hybrid Education of Veterinary Anatomy

At this point, plastinated specimens distinguish by their advantageous features. Various techniques can be recommended for hybrid learning of veterinary anatomy through plastinated specimens (Figure 3).

The first stage of hybrid learning in anatomy is undoubtedly face-to-face or in-person activities. Plastinated specimens have proved their effectiveness in regular face-to-face education in recent years. Due to their simulation capacity of anatomic structures as in their natural appearance, plastinates became essential learning materials for anatomy practices. In order to reduce the negative effects of fixated cadavers for the learners in practice, plastinates come to the front with non-hazardous features (24, 40).

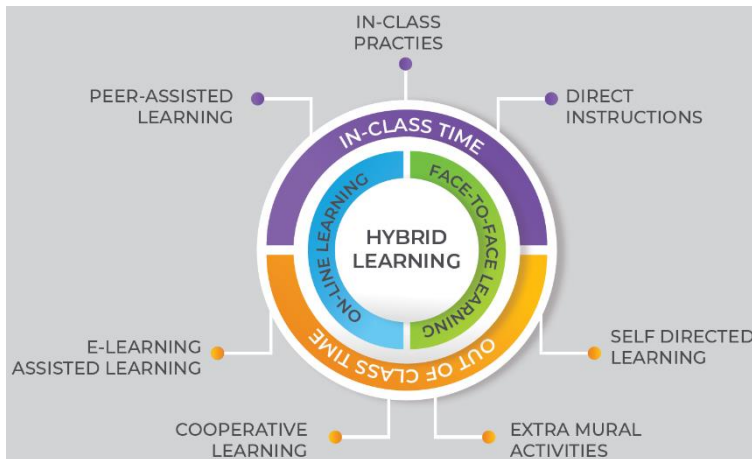


Figure 3. Convenient techniques for hybrid learning of veterinary anatomy by using plastinated specimens.



Figure 4. While trainers are performing on-line practical sessions or e-learning videos on the cadavers or plastinates, on-line learners can practice simultaneously on their plastinated specimens.

Fresh organs or cadavers are always a gold standard for anatomy education. However, fresh specimen means using the body or body part of an individual that will be sacrificed somehow for this purpose. Besides, the short-time use necessity of fresh cadavers can be a struggling limitation for the trainers in terms of fast decomposition or microbiological activity (40). However, the primary desire of the instructors is to be able to use the convenient learning materials for a longer period of time in order to perform various in-class or hybrid education techniques (32). Therefore, fresh specimens may be the first choice instead of plastinated specimens for such kind of long-term practical trainings (40). The increased student groups mean extra learning materials for practice (5). If you have even a basic silicone plastination lab working properly, providing various plastinated specimens for student groups will be an effective way to support the face-to-face part of hybrid learning (24).

The second method of hybrid learning, as mentioned above, is to combine in-person and on-line training for the learners (15). Thanks to durable, non-toxic and non-hazardous properties, plastinates can easily be transferred, handled or shared with the learners. While trainers are performing practical lectures on the cadavers or plastinates, on-line learners can practice simultaneously on their plastinated specimens which were provided previously (Figure 4).

In instructor-centered processes, learners cannot gain enough self-confidence and autonomy. Therefore, they cannot develop self-directed learning skills (4). However, self-directed learning and peer-assisted learning are another effective tools not only for in-class activities, but also for hybrid education (6, 25). Learners can acquire skills such as greater autonomy, self-sufficiency and developing a critical perspective with a well-designed hybrid learning processes. At this point, it is important to

use abstract and concrete techniques together in the use of educational technologies (4). While studying through pre-recorded videos or similar e-learning materials, the presence of anatomical practice materials for the learners increases the efficiency of self-directed or peer-assisted learning even in the class or out of class learning times. However, this type of learning, without supervision, would be risky in terms of biological safety or lab security regulations when classical fixated cadavers or fresh specimens are used. Plastinated specimens can overcome this problem with the specified features mentioned above (40). Learners can make use of plastinates either in the labs or any related extramural training facilities (Figure 5).

Today's students are expected to be lifelong learners throughout their student and professional lives. Therefore,

university trainings should also be designed to self-directed learning in real-life working areas beyond formal education. This can be achieved by hybrid learning configurations where working and learning are integrated together (6). Within this scope, extramural learning can also be used for the hybrid education. Extramural assignments are an essential part of practical learning as they provide a unique opportunity for learners to gain professional experience and practical skills acquired during clinical anatomy education (3, 22, 28). Production of goal-directed plastinates and transferring the specimens to the related facilities may provide an effective extramural learning period not only for the anatomy students, but also for the clinical anatomy trainees who are willing to take professional skills from various establishments (Figure 6).



Figure 5. Self-directed or peer-assisted learning, without supervision, would be risky in terms of biological safety or lab security regulations when classical fixated cadavers or fresh specimens are used. Plastinated specimens can overcome this problem with their unique properties.



Figure 6. Production of goal-directed plastinates will provide an effective extramural learning period not only for the anatomy students, but also for the clinical anatomy trainees who are willing to take professional skills.

Mahdy and Ewaida mentioned that the need of technological tools such as internet connection and electronic devices could be a problem for on-line learners during pandemic period. Unstable network connection in different regions, problems to join on-line learning, interrupted electricity connection, imperative social isolation, ocular problems because of screen use, and lack of appropriate learning environment at home were the major deficiencies (26). Karadağ and Yücel (20) reported that only 63% of the university students have an internet connection at home, 66% have a computer or tablet in Türkiye. And 23% of the learners stated that they could not continue their distance education (20). Therefore, the necessity of active use of plastinates and similar anatomical education materials not only in on-line education but also in hybrid learning or in-class practices should be taken into consideration.

Routh et al. mentioned that institutional cultural resistance can be occurred in various establishments while transition to on-line education in extraordinary situations like outbreaks (34). Despite all these negative approaches, the use of plastinates in hybrid learning can be an alternative to gradually reducing resistance in trainers who believe in traditional education methods.

Conclusion

The experiences in the last 3 years have proved us that nothing will ever be the same again in many different fields, especially in education. If instructors want to bring much more competent colleagues to veterinary profession, they have to adapt to these changing-developing processes. In this review, we wanted to convey to the readers the usage areas of plastination in hybrid learning, which can be an effective learning tool for changing veterinary education. The opinions and suggestions expressed in this article will be carried to much more useful points with scientific studies on the subject and different techniques to be applied to target groups.

Conflict of Interest

The authors declared that there is no conflict of interest.

Data Availability Statement

The data supporting this study's findings are available from the corresponding author upon reasonable request.

Author Contributions

OE conceived and planned the concept and content of the review. OE, CB, BB and ST contributed to the retrospective analyses of the current techniques. OE and CB contributed to the interpretation of the data. OE took the lead in writing the manuscript.

References

1. Bakıcı C, Yunus HA, Batur B, et al (2023): *Anatomical Evaluation and Preparation Procedure of a cross-sectioned Kidney Plastination of A Thoroughbred Horse with Local Polyester Resin*. Ankara Univ Vet Fak Derg, 1 - 17.
2. Baptista CA, DeJong K, Latorre R, et al (2019): *P40 polyester sheet plastination technique for brain and body slices: The vertical and horizontal flat chamber methods*. Anat Histol Embryol, **48**, 572-576.
3. Bell C, Baillie S, Kinnison T, et al (2010): *Preparing veterinary students for extramural clinical placement training: issues identified and a possible solution*. J Vet Med, **37**, 190-197.
4. Bozkurt A (2020): *Koronavirüs (Covid-19) pandemi süreci ve pandemi sonrası dünyada eğitime yönelik değerlendirmeler: Yeni normal ve yeni eğitim paradigması*. AUAd, **6**, 112-142.
5. Contreras GW (2020): *Getting ready for the next pandemic COVID-19: Why we need to be more prepared and less scared*. J Emerg Manag, **18**, 87-89.
6. Cremers PH, Wals AE, Wesselink R, et al (2014): *Self-directed lifelong learning in hybrid learning configurations*. Int J Lifelong Educ, **33**, 207-232.
7. DeJong K, Henry RW (2007): *Silicone plastination of biological tissue: Cold-temperature technique Biodur™ S10/S15 Technique and Products*. J Int Soc Plastination, **22**, 2-14.
8. Durak G, Çankaya S, İzmirli S (2020): *COVID-19 pandemi döneminde Türkiye'deki üniversitelerin uzaktan eğitim sistemlerinin incelenmesi*. EFMED, **14**, 787-809.
9. Durbach N (2014): *"Skinless wonders": body worlds and the Victorian freak show*. J Hist Med Allied Sci, **69**, 38-67.
10. Eken Ö, Tosun N, Eken DT (2020): *Covid-19 salgını ile acil ve zorunlu uzaktan eğitime geçiş: Genel Bir Değerlendirme*. Milli Eğitim Dergisi, **49**, 113-128.
11. Ekim O (2018): *Efficiency evaluation of different silicone plastination protocols applied to domestic avian specimens*. Vet Hekim Der Derg, **89**, 74-84.
12. Ekim O (2020): *Pandemilerde Çocuk ve Hayvan İlişkisi*. 151-154. In: İ Bostancı (Ed), Çocuk Sağlığında SARS-CoV-2 (COVID-19). Türkiye Klinikleri.
13. Ekim O, Hazıroğlu RM, İnsal B, et al (2017): *A modified S10B silicone plastination method for preparation and preservation of scaled reptile specimens*. Ankara Univ Vet Fak Derg, **64**, 155-160.
14. Ekim O, Tunali S, Hazıroğlu RM, et al (2014): *Evcil memeli hayvanlarda böbreklerin soğuk ortam tekniği ile silikon plastinasyonu*. Vet Hekim Der Derg, **85**, 1-11.
15. Eyal L, Gil E (2022): *Hybrid Learning Spaces-A Three-Fold Evolving Perspective*. 11-24. In: E Gil, Y Mor, Y Dimitriadis, et al (Ed), Hybrid Learning Spaces. Springer, Switzerland.
16. Gorbalenya AE (2020): *Severe acute respiratory syndrome-related coronavirus—The species and its viruses, a statement of the Coronavirus Study Group*. Nat Microbiol, **5**, 536-544.
17. Haldane V, De Foo C, Abdalla SM, et al (2021): *Health systems resilience in managing the COVID-19 pandemic: lessons from 28 countries*. Nat Med, **27**, 964-980.

18. Henry RW, Janick L, Henry C (1997): *Specimen preparation for silicone plastination*. J Int Soc Plastination, **12**, 13-17.
19. Jaquis WP, Schneider SM (2021): *Preparing for the Next Pandemic*. Ann Emerg Med, **78**, 212-219.
20. Karadağ E, Yücel C (2020): *Yeni tip Koronavirüs pandemisi döneminde üniversitelerde uzaktan eğitim: Lisans öğrencileri kapsamında bir değerlendirme çalışması*. Yükseköğretim Dergisi, **10**, 181-192.
21. Khan M, Adil SF, Alkhathlan HZ, et al (2020): *COVID-19: a global challenge with old history, epidemiology and progress so far*. Molecules, **26**, 39.
22. Kornienko DV, Shcherbatykh SV, Mishina SV, et al (2020): *The effectiveness of the pedagogical conditions for organizing the educational process using educational technologies at the university*. J Phys Conf, **1691**, 012090.
23. Latorre R, Arencibia A, Gil F, et al (2003): *P-40 and S10 plastinated slices: an aid to interpreting MR images of the equine tarsus*. J Int Soc Plast, **18**, 14-22.
24. Latorre RM, Garcia-Sanz MP, Moreno M, et al (2007): *How useful is plastination in learning anatomy?* J Vet Med, **34**, 172-176.
25. Lee YM, Mann KV, Frank BW (2010): *What drives students' self-directed learning in a hybrid PBL curriculum*. Adv in Health Sci Educ, **15**, 425-437.
26. Mahdy MA, Ewaida ZM (2022): *Evaluation of the emergency remote learning of veterinary anatomy during the COVID-19 pandemic: global students' perspectives*. Front Educ, **6**, 1-12.
27. Mahdy MA, Sayed RK (2022): *Evaluation of the online learning of veterinary anatomy education during the Covid-19 pandemic lockdown in Egypt: Students' perceptions*. Anat Sci Educ, **15**, 67-82.
28. Nikolopoulou K (2022): *Face-to-face, online and hybrid education: University students' opinions and preferences*. J Digit Educ Technol, **2**, ep2206.
29. Pashaei S (2010): *A brief review on the history, methods and applications of plastination*. Int J Morphol, **28**, 1075-1079.
30. Pendovski L, Petkov V, Popovska-Percinic F, et al (2008): *Silicone plastination procedure for producing thin, semitransparent tissue slices: A study using the pig kidney*. J Plas, **23**, 10-16.
31. Phelan AL, Katz R, Gostin LO (2020): *The novel coronavirus originating in Wuhan, China: challenges for global health governance*. Jama, **323**, 709-710.
32. Raes A, Vanneste P, Pieters M, et al (2020): *Learning and instruction in the hybrid virtual classroom: An investigation of students' engagement and the effect of quizzes*. Comput Educ, **143**, 103682.
33. Riederer BM (2014): *Plastination and its importance in teaching anatomy. Critical points for long-term preservation of human tissue*. J Anat, **224**, 309-315.
34. Routh J, Paramasivam SJ, Cockcroft P, et al (2021): *Veterinary education during COVID-19 and beyond—challenges and mitigating approaches*. Animals, **11**, 1818.
35. Sargon MF, Tatar İ (2014): *Plastination: basic principles and methodology*. Anatomy, **8**, 13-18.
36. Sora MC (2007): *Epoxy plastination of biological tissue: E12 ultra-thin technique*. J Int Soc Plastination, **22**, 40-45.
37. Telli SG, Altun D (2021): *Koronavirüs (Covid-19) pandemisi döneminde çevrimiçi öğrenme*. Üniversite Araştırmaları Dergisi, **4**, 90-107.
38. Üstün Ç (2002): *Plastination. Is it a Science or a Freak Show?* Meandros Med Dental J, **3**, 37-42.
39. Weber W, Weiglein A, Latorre R, et al (2007): *Polyester plastination of biological tissue: P35 technique*. J Int Soc Plastination, **22**, 50-58.
40. Yunus HA, Ekim O, Bakıcı C, et al (2022): *A. From toxic cadavers to biosafe specimens: a brief history of plastination in veterinary anatomy*. Vet Hekim Der Derg, **93**, 158-165.
41. Zilio LD, Ampuero JP (2023): *Earthquake doublet in Turkey and Syria*. Commun Earth Environ, **4**, 71.

Publisher's Note

All claims expressed in this article are solely those of the authors and do not necessarily represent those of their affiliated organizations, or those of the publisher, the editors and the reviewers. Any product that may be evaluated in this article, or claim that may be made by its manufacturer, is not guaranteed or endorsed by the publisher.
