

# Head and neck tumors detected in dogs and cats between 2011 and 2021: A retrospective study

Gözde YÜCEL TENEKECI<sup>1,a,✉</sup>, Oya Burçin DEMİRTAŞ<sup>1,b</sup>, Osman KUTSAL<sup>1,c</sup>, Sevil ATALAY VURAL<sup>1,d</sup>

<sup>1</sup>Ankara University, Faculty of Veterinary Medicine, Department of Pathology, Ankara, Türkiye

<sup>a</sup>ORCID: 0000-0002-2586-8346; <sup>b</sup>ORCID: 0000-0003-0850-2374; <sup>c</sup>ORCID: 0000-0003-3599-6867; <sup>d</sup>ORCID: 0000-0003-2111-3381

## ARTICLE INFO

### Article History

Received : 01.11.2022

Accepted : 07.09.2023

DOI: 10.33988/auvfd.1197926

### Keywords

Benign

Cat

Dog

Malignant

Tumor

### ✉Corresponding author

gozdeyucel@gmail.com

**How to cite this article:** Yücel Tenekeci G, Demirtaş OB, Kutsal O, Atalay Vural S (2024): Head and neck tumors detected in dogs and cats between 2011 and 2021: A retrospective study. Ankara Univ Vet Fak Derg, 71 (3), 281-289. DOI: 10.33988/auvfd.1197926.

## ABSTRACT

The aim of this study is to determine and compare the distribution, localization, breed, age and gender incidences of head and neck region tumors by years, by evaluating the results of dog-cat biopsies and/or operation material brought to Ankara University, Faculty of Veterinary Medicine, Department of Pathology between the years 2011 and 2021. In the study, 244 (15.9%) of 1533 tumors diagnosed in dogs and cats between 2011 and 2021 belonged to the head and neck region, of which 159 were in dogs and 85 in cats. Dogs with tumors were generally more than 6 years old (n=108) and cats were mostly 1 year old and older (n=75). In the head and neck region tumors observed in dogs, malignant and benign tumors of epithelial origin were most common (n=81; 50.9%), with sebaceous tumors (n=22) being the most common, and mostly observed around the eyes (n=26), while malignant and benign tumors of mesenchymal origin were most commonly found in the mouth region. Among the tumors of this region, epithelial tumors were mostly encountered in cats (n=39, 45.8%), and 51.2% of the epithelial tumors were squamous cell cancer (n=20), with epithelial tumors being the most common in the mouth (n=12) and nose (n=9). As a result, epithelial malignant and benign tumors were mostly seen in the eyes, and mesenchymal malignant and benign tumors were detected in the mouth. Among tumor types, papilloma in benign tumors and squamous cell carcinoma in malignant tumors were noted.

## Introduction

Tumor formations are common in dogs and cats. Where skin, mammae, uro-genital system, spleen and soft tissue come to the fore in dogs according to their anatomical-topographic features; in cats, it has been reported frequently in the eyes, digestive system, nasal cavity, lymph nodes, bones and mammae (10). Although skin tumors can be seen in almost every part of the body, localization differs according to the cells from which they originate. As a matter of fact, squamous cell and basal cell cancers, which are frequently seen, are especially localized in the head and neck region (4, 11).

Studies on the head and neck region are limited. These tumors in dogs are mostly presented as survey studies and these tumors constitute 7% of all canine tumors. Half of these are malignant tumors and consist of squamous cell cancer, melanocytic tumors, soft tissue sarcomas and adenocarcinomas, respectively (1, 11). In

cats, head and neck tumors were mostly observed in the mouth region and epulis were frequently mentioned (12).

Although the age range, breed and gender predisposition of head and neck region tumors shows equality, it has been reported that especially oro-pharyngeal region tumors are observed in young terrier or mixed breed dogs and old tabby cats, often in females (10, 12).

In the study, the results of canine-cat biopsy and/or operation material brought to Ankara University Faculty of Veterinary Medicine Department of Pathology between 2011 and 2021 were evaluated, and the results of tumors in the head and neck region (including skin, ear, eye, nose, brain, skull, oropharyngeal region and mouth) were evaluated over the years. It was aimed to determine and compare their distribution, localization, race, age and gender incidences according to each other. With this retrospective study, in which tumor data observed in the head and neck region over a ten-year period were

examined in detail, it was thought to contribute to both veterinary pathology and clinicians as a result of sharing up-to-date data.

## Materials and Methods

The material for the study consisted of biopsy and/or operation materials from 1399 dogs and 587 cats, which were examined in the Pathology Department of Ankara University Faculty of Veterinary Medicine between 2011 and 2021. Tumors were detected in 1100 dogs and 433 cats from these materials. Among them, those belonging to the head and neck region were evaluated.

**Sampling:** 1 cm thick samples were taken from the materials and fixed in 10% formaldehyde solution. These were then routinely processed, embedded in paraffin blocks, and 5 µm thick sections were taken and stained with hematoxylin & eosin. Afterwards, the sections were examined under a light microscope.

Primarily, the distribution of these tumors by years, breed and age details in dogs and cats, localizations (skin, ear, eye, nose, brain, skull and mouth (including the oropharyngeal region)) are detailed in Tables 1, 2, 3 and 4. Although it was adhered to the original data in the records of the Department in the diagnosis of tumors, Meuten (8) was used for nomenclature and classification. When the diagnoses were evaluated in general, they were interpreted after being divided into six groups: as epithelial tumors, mesenchymal tumors, melanocytic tumors, odontogenic tumors, nervous system tumors and other tumors. In some cases involving the head and neck region, the location of the tumor was not specified. These are included in the “skin, localization not-specified” section.

## Results

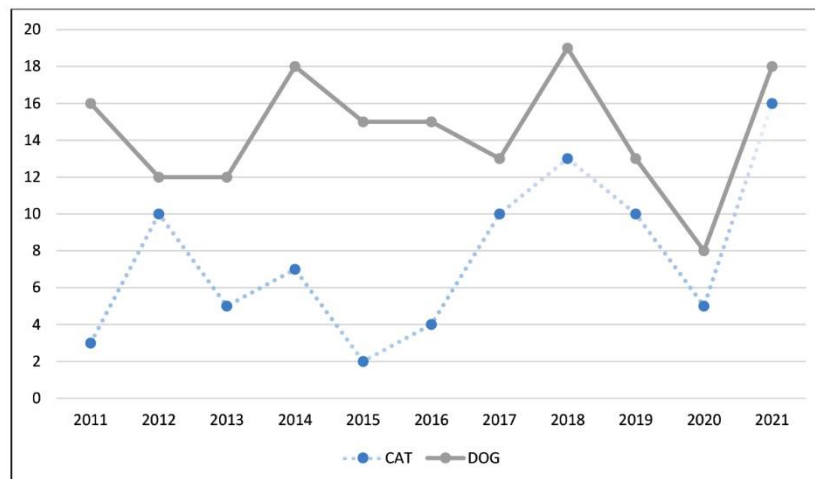
In this study, 244 (15.9%) of 1533 tumors diagnosed in dogs and cats between 2011 and 2021 belonged to the head

and neck region. Of these, 159 were in dogs and 85 were in cats. Two different tumors were detected simultaneously in six dogs and two cats. It was determined that 14.4% of the detected tumors in dogs and 19.6% in cats were seen in the head and neck region. The distribution of head and neck tumors in dogs and cats by years is given in Figure 1. Accordingly, head-neck region tumors were most common in dogs in 2018 (n=19, 11.8%); in cats, they were most commonly observed in 2021 (n=16, 18.6%).

Of the dogs with tumors, 71 were female, 70 were male, whereas 38 of the cats were male and 41 were female. The genders of 14 dogs and 5 cats were not specified.

It was noted that commonly, dogs with these tumors were older than 6 years (n=108) and cats were 1 year and older (n=75). The distribution of animals according to breeds and age ranges is given in Tables 1 and 2.

Tumors in dogs were found in Terrier (n=21), German Shepherd (n=11), Boxer (n=8), Golden Retriever (n=25), Pekignese (n=2), Bulldog (n=2), Labrador (n=3), Rottweiller (n=1), Cocker Spaniel (n=11), American Cocker Spaniel (n=1), Kangal (n=4), Husky (n=4), Japanese Spaniel (n=1), King Charles Cavalier Spaniel (n=3), Jack Russell Terrier (n=1), Alaskan Malamute (n=1), Chow Chow (n=1), Pomeranian (n=1), and mixed (n=29) breeds. In cats, tumors were observed in Orange Tabby (n=8), Siameese (n=1), Tabby (n=14), Turkish Van (n=1), Turkish Angora (n=8), Himalayan (n=1), Bombay (n=1), Persian (n=1), and mixed (n=33) breeds. The breeds of 31 dogs and 19 cats were not specified. When evaluated, except for those of unknown breed, head-neck region tumors were mostly observed in crossbreeds in both dogs and cats. While the most common breeds in dogs after crossbreeds were Golden Retriever and Terrier, respectively; Tabby was the most common breed in cats.



**Figure 1.** Distribution of the number of head and neck tumors in dogs and cats by years.

**Table 1.** Breed and age distributions of dogs with head and neck region tumors.

Breed	Age 0-1	Age 1-5	Age 6-10	Age 11 +	Age Unknown	Total
Terrier	1	2	5	12	1	21
German Shepherd	1	3	5	2	-	11
Boxer	-	-	4	3	1	8
Golden Retriever	1	3	12	8	1	25
Pekingese	-	-	1	1	-	2
Bulldog	-	2	-	-	-	2
Labrador Retriever	-	-	3	-	-	3
Rottweiler	-	-	1	-	-	1
Cocker Spaniel	-	-	5	6	-	11
American Cocker Spaniel	-	1	-	-	-	1
Sivas Kangal	-	-	3	-	-	3
Husky	-	1	1	2	-	4
Japon Spaniel	-	-	-	1	-	1
King Charles Cavalier Spaniel	-	-	1	-	2	3
Jack Russell Terrier	1	-	-	-	-	1
Malamute	-	-	1	-	-	1
Pomeranian	-	-	1	-	-	1
Chow chow	-	-	1	-	-	1
Mixed	1	10	8	7	2	28
Unknown	-	6	8	9	8	31
<b>Total</b>	5	28	60	51	15	159

**Table 2.** Breed and age distributions of cats with head and neck region tumors.

Breed	Age 0-1	Age 1-5	Age 6-10	Age 11 +	Age Unknown	Total
Orange Tabby	-	2	2	3	1	8
Siameese	-	-	1	-	-	1
Tabby	-	5	2	5	2	14
Turkish Van	-	-	1	-	-	1
Turkish Angora	-	1	5	1	1	8
Himalayan	-	1	-	-	-	1
Bombay	-	1	-	-	-	1
Persian	-	1	-	-	-	1
Mixed	3	11	12	8	1	35
Unknown	1	2	6	6	4	19
<b>Total</b>	4	24	29	23	9	89

**Table 3.** Canine Head-Neck Tumors.

Tumor Types	Localization									Total
	Eye	Nose	Sinus	Mouth	Skin	Ear	Neck	Brain	Cranium	
<b>Epithelial Tumors</b>										
<b>Benign Epithelial Tumors</b>										
Papilloma	2	-	-	5	1	1	-	-	-	9
Adenoma	2	-	-	-	1	-	-	-	-	3
Cutaneous Sebaceous Epithelioma	1	-	-	-	-	-	-	-	-	1
Meibomian Adenoma	5	-	-	-	-	-	-	-	-	5
Sebaceous Adenoma	1	-	-	1	-	2	-	-	-	4
Sebaceous Ductal Adenoma	-	-	-	-	-	1	-	-	-	1
Ceruminous Adenoma	-	-	-	-	-	1	-	-	-	1
Trichoblastoma	1	-	-	-	1	1	-	-	-	3
<b>Malign Epithelial Tumors</b>										
Mix Ceruminous Carcinoma	-	-	-	-	-	1	-	-	-	1
Meibomian Carcinoma	2	-	-	-	-	-	-	-	-	2
Ceruminous Adenocarcinoma	7	-	-	-	1	-	1	-	-	9
Squamous Cell Carcinoma	3	-	2	5	3	3	-	-	-	16
Indifferental Squamous Cell Carcinoma	-	-	1	1	1	-	-	-	-	3
Basal Cell Carcinoma	1	-	-	-	2	5	1	-	-	9
Baso-squamous Cell Carcinoma	1	-	-	-	-	1	-	-	-	2
Adenocarcinoma	-	-	2	-	-	-	-	-	-	2
Sweat Gland Carcinoma	-	-	-	-	1	-	1	-	-	2
Solid Carcinoma	-	-	-	2	-	-	-	-	-	2
Ethmoidal Adenocarcinoma	-	-	1	-	-	-	-	-	-	1
Cystic Papillary Adenocarcinoma	-	-	-	-	-	1	-	-	-	1
Indifferental Carcinoma	-	1	-	-	-	-	-	-	-	1
Nasal Carcinoma	-	1	1	-	-	-	-	-	-	2
Indifferental Nasal Carcinoma	-	-	1	-	-	-	-	-	-	1
Total	26	2	8	14	11	17	3	-	-	81
<b>Mesenchymal Tumors</b>										
<b>Benign Mesenchymal Tumors</b>										
Lipoma	-	-	-	-	-	-	2	-	-	2
Fibromyoma	-	-	-	1	-	-	-	-	-	1
Chondroma	-	-	-	-	-	-	1	-	-	1
Chondroosteoma	-	-	-	-	-	1	-	-	-	1
<b>Malign Mesenchymal Tumors</b>										
Fibrosarcoma	-	-	1	1	-	-	1	-	-	3
Chondrosarcoma	-	1	1	1	-	-	-	-	1	4
Osteosarcoma	1	1	2	-	-	-	-	-	1	5
Rhabdomyosarcoma	-	-	-	3	-	-	-	-	-	3
Fibromyxolipochondro-osteosarcoma	1	-	-	-	-	-	-	-	-	1
Hemangiosarcoma	-	-	-	1	-	-	1	-	-	2
Hemangioendothelioma malignum	1	-	-	-	-	-	-	-	-	1
Total	3	2	4	7	-	1	5	-	2	24

<b>Melanocytic Tumors</b>										
<b>Benign Melanocytic Tumors</b>										
Benign Melanoma	5	1	-	1	-	-	-	-	-	7
Amelanotic Melanoma	1	-	-	2	-	-	-	-	-	3
<b>Malign Melanocytic Tumors</b>										
Malign Melanoma	-	1	-	6	-	1	-	-	-	8
Amelanotic Malign Melanoma	-	-	-	-	-	1	-	-	-	1
<b>Total</b>	<b>6</b>	<b>2</b>	<b>-</b>	<b>9</b>	<b>-</b>	<b>2</b>	<b>-</b>	<b>-</b>	<b>-</b>	<b>19</b>
<b>Odontogenic Tumors</b>										
Epulis Granulomatosis	-	-	-	1	-	-	-	-	-	1
Fibromatous Epulis	-	-	-	1	-	-	-	-	-	1
Ossified Epulis	-	-	-	1	-	-	-	-	-	1
Odontogenic Fibroma	-	-	-	2	-	-	-	-	-	2
Ameloblastoma	-	-	-	2	-	-	-	-	-	2
Ameloblastic fibroadenoma	-	-	-	2	-	-	-	-	-	2
<b>Total</b>	<b>-</b>	<b>-</b>	<b>-</b>	<b>9</b>	<b>-</b>	<b>-</b>	<b>-</b>	<b>-</b>	<b>-</b>	<b>9</b>
<b>Nervous System Tumors</b>										
Meningothelial Meningioma	-	-	-	-	-	-	-	1	-	1
Oligodendroglioma	-	-	-	-	-	-	-	2	-	2
Indifferent Astrocytoma	-	-	-	-	-	-	-	1	-	1
Psammomatous Meningioma	-	-	-	-	-	-	-	1	-	1
<b>Total</b>	<b>-</b>	<b>-</b>	<b>-</b>	<b>-</b>	<b>-</b>	<b>-</b>	<b>-</b>	<b>5</b>	<b>-</b>	<b>5</b>
<b>Other Tumors</b>										
Extragenital TVT	1	-	1	-	2	-	-	-	-	4
Mastocytoma	-	-	1	1	1	1	-	-	-	4
Histiocytoma	1	-	-	-	-	-	-	-	-	1
Cutaneous Histiocytoma	-	-	-	-	-	3	-	-	-	3
Atypical Histiocytoma	-	-	-	1	-	-	-	-	-	1
Malignant Fibrous Histiocytoma	-	-	-	2	-	-	-	-	-	2
Round Cell Tumor	1	-	-	-	-	-	1	-	-	2
Plasmacytoma	1	-	-	2	-	-	-	-	-	3
Lymphoma	-	-	-	-	-	-	1	-	-	1
<b>Total</b>	<b>4</b>	<b>-</b>	<b>2</b>	<b>6</b>	<b>3</b>	<b>4</b>	<b>2</b>	<b>-</b>	<b>-</b>	<b>21</b>
<b>TOTAL TUMORS</b>	<b>39</b>	<b>6</b>	<b>14</b>	<b>45</b>	<b>14</b>	<b>24</b>	<b>10</b>	<b>5</b>	<b>2</b>	<b>159</b>
	24.5%	3.7%	8.8%	28.3%	8.8%	15.0%	6.2%	3.1%	1.2%	

Epithelial tumors were most common in the head and neck region of dogs (n=81, 50.9%). The most common epithelial benign tumors were sebaceous tumors (n=11) and most of them were in the eye (n=7). The most common tumor type after sebaceous tumors was papillomas (n=9) most of which were found in the mouth region. Epithelial malignant tumors (n=54) were observed more frequently than benign ones (n=27). The most common epithelial malignant tumor was squamous cell carcinoma (n=19), 9.2% of which were in the mouth. Although there was no significant difference between tumor types of

mesenchymal origin (n=24, 15.0%) in dogs, they were frequently encountered in the mouth region (n=7). Also in the head and neck region, other tumors including melanocytic tumors (n=19, 11.9%), odontogenic tumors (n=9, 5.6%), nervous system tumors (n=5, 3.1%), and usually round cell tumors (n=21, 13.2%) were observed. It was noted that the most common head and neck tumors observed in dogs were in the mouth (n=45, 28.3%), in the nose (n=6, 3.7%), in the sinus (n=14, 8.8%) and in the eye (n=39, 24.5%). The types and localizations of the tumors are detailed in Table 3.

**Table 4.** Feline Head-Neck Tumors.

Tumor Types	Localization									
	Eye	Nose	Sinus	Mouth	Skin	Ear	Neck	Brain	Cranium	Total
<b>Epithelial Tumors</b>										
<b>Benign Epithelial Tumors</b>										
Polyp	-	1	-	-	-	-	-	-	-	1
Squamous cell papilloma	-	-	-	1	-	-	-	-	-	1
<b>Malign Epithelial Tumors</b>										
Squamous Cell Carcinoma	1	4	-	8	-	2	1	-	-	16
Basal Cell Carcinoma	-	-	-	-	-	1	-	-	-	1
Baso-squamous Cell Carcinoma	2	2	-	1	1	-	-	-	-	6
Papillary Cystic Adenocarcinoma	-	1	-	-	-	1	-	-	-	2
Indifferental Squamous Cell Carcinoma	-	1	1	1	-	-	1	-	-	4
Carcinoma	-	-	-	-	-	1	-	-	-	1
Adenocarcinoma	-	-	-	1	-	-	-	-	-	1
Indifferental Carcinoma	1	-	1	-	-	-	-	-	-	2
Apocrine Carcinoma	-	-	-	-	-	1	-	-	-	1
Acinar Cell Carcinoma	-	-	-	-	-	-	1	-	-	1
Nasal Carcinoma	-	-	2	-	-	-	-	-	-	2
Total	4	9	4	12	1	6	3	-	-	39
<b>Mesenchymal Tumors</b>										
<b>Benign Mesenchymal Tumors</b>										
Fibroma	-	1	-	-	-	2	-	-	-	3
Fibromyxoma	-	-	-	-	-	1	-	-	-	1
Fibrochondroosteoma	-	1	-	-	-	-	-	-	-	1
Hemangioma capillare	-	-	-	1	-	-	-	-	-	1
Hemangioendothelioma	-	-	-	-	1	-	-	-	-	1
<b>Malign Mesenchymal Tumors</b>										
Fibrosarcoma	-	-	-	-	-	1	-	-	-	1
Fibromyosarcoma	-	-	-	-	-	1	2	-	-	3
Fibromyxosarcoma	-	-	-	-	-	-	1	-	-	1
Fibromyxomyosarcoma	-	-	-	-	-	-	1	-	-	1
Hemangiosarcoma	-	1	1	1	-	-	-	-	-	3
Osteosarcoma	-	-	-	1	-	-	-	-	-	1
Giant Cell Osteosarcoma	-	1	-	-	-	-	1	-	-	2
Osteoblastic Osteosarcoma	-	-	-	-	-	-	-	-	1	1
Giant Cell Sarcoma	-	-	-	-	-	-	1	-	-	1
Nasal Sarcoma	-	1	-	-	-	-	-	-	-	1
Total	-	5	1	3	1	5	6	-	1	22
<b>Melanocytic Tumors</b>										
Melanoma	3	-	-	-	-	-	-	-	-	3
Malign Melanoma	1	-	-	-	-	-	-	-	-	1
Total	4	-	-	-	-	-	-	-	-	4
<b>Odontogenic Tumors</b>										
Giant Cell Epulis	-	-	-	1	-	-	-	-	-	1
Ameloblastoma	-	-	-	1	-	-	-	-	-	1
Total	-	-	-	2	-	-	-	-	-	2

Nervous System Tumors											
Fibroblastic Meningioma	-	-	-	-	-	-	-	-	1	-	1
Peripheral Nerve Sheath Tumor	-	-	-	-	1	-	-	-	-	-	1
Transitional Meningioma	-	-	-	-	-	-	-	1	-	-	1
Psammomatous Meningioma	-	-	-	-	-	-	-	1	-	-	1
Meningioma	-	-	-	-	-	-	-	1	-	-	1
Total	-	-	-	-	1	-	-	4	-	-	5
Other Tumors											
Plasmacytoma	-	-	-	7	-	-	-	-	-	-	7
Round Cell Tumor	-	-	-	2	-	-	-	-	-	-	2
Round Cell Sarcoma	-	-	-	1	-	-	-	-	-	-	1
Histiocytoma	-	-	-	1	-	-	-	-	-	-	1
Lymphoma	-	-	-	1	-	-	-	-	-	-	1
Mastocytoma	-	-	-	-	-	-	1	-	-	-	1
Total	-	-	-	12	-	-	2	-	-	-	13
<b>TOTAL TUMORS</b>	8	14	5	29	3	11	10	4	1	-	85
	9.4%	16.4%	5.8%	34.1%	3.5%	12.9%	11.7%	4.7%	1.1%		

Epithelial tumors were most frequently observed in cats (n=39), with a relatively small number of benign tumors (n=2). Squamous cell carcinoma (n=20) constituted 54% of epithelial malignant tumors, and half of them were in the mouth region. When epithelial tumors were considered as general localization; they were most frequently observed in the mouth (n=12) and nose (n=9). No significant difference was observed between the types of tumors of mesenchymal origin (n=22, 25.8%). Other tumors in the head and neck region also include melanocytic tumors (n=4, 4.7%), odontogenic tumors (n=2, 2.3%), nervous system tumors (n=5, 5.8%), and round cell tumors (n=13, 15.2%). It was noted that the head and neck tumors observed in cats were mostly located in the mouth (n=29, 34.1%) and nose (n=14, 16.4%). The types and localizations of these tumors are given in Table 4.

## Discussion and Conclusion

Diseases, tumors and types of cases observed in animals, their incidence, and distribution according to identity information emerge as a result of screening and research carried out within a certain period of time. Especially in the examination of tumoral cases in domestic animals, cities such as Ankara, where the rate of dog and cat feeding is high and conscious populations are interested in animals, gain importance (3, 6, 7, 9, 12). In this study, the types and distributions of head and neck tumors, which are frequently observed in dogs and cats, were examined and compared over an 11-year period. By this, actuality and continuity of results of the study by Kutlu et al. in Ankara University Faculty of Veterinary Medicine Department of Pathology will also be provided.

Considering the age range in which head and neck tumors were seen, it was observed that the average decreased to earlier ages. It is known that the incidence of tumors increases with age in domestic animals. Kutlu et al. (7) in their study examining the tumors observed in the head region that the average age was 10 years in dogs and 11 years in cats between 2000 and 2010. Contrary to a similar study (7), which reported that there was no significant difference between breeds when racial predisposition was examined, the most common breeds in dogs after crossbreeds were Golden Retriever and Terrier, respectively; in cats, it was observed that Tabby is the most common. Despite these results, it is thought that breed predisposition should be considered according to tumor types. For example, melanomas, which are common in the head region from skin and mouth tumors, are more common in dark-colored breeds with more intense pigment. In our study, it was reported that sebaceous tumors, one of the most frequently observed tumors, were mostly observed in English Cocker Spaniel, Cocker Spaniel, Siberian Husky, Samoyed, and Alaskan Malamute (4).

In the study, Kutlu et al. (7) similarly did not report any gender differences in the occurrence of head tumors in dogs, but they found that they were more common in female cats than in male cats. In a study investigating head and neck tumors in dogs, it was reported that they were more common in females than males (1). When the genders of dogs and cats were evaluated, it was seen that the percentage of males and females was approximately 50%.

Tumors detected in this study were considered as epithelial, mesenchymal tumors, melanocytic tumors, odontogenic tumors, nervous system tumors and other



tumors, considering their diagnoses. Accordingly, it was noted that tumors of epithelial origin (n=81), especially malignant ones (n=54) were observed most frequently in dogs and cats. In the studies, the most common melanomas in the head region in dogs (1); and squamous cell cancer (1) are; odontogenic tumors, papillomas, (12) and melanomas (12) in the oropharyngeal region (2, 5). Although this study is partially similar to some others (1, 12) due to the prevalence of epithelial tumors, it was found that sebaceous gland tumors were most common among the epithelial tumors. These tumors, which are generally classified as sebaceous adenoma, sebaceous ductal adenoma, sebaceous epithelioma and sebaceous carcinoma, have been reported to occur frequently in the head region, especially in dogs (4). They were observed most frequently in the mouth and eyes, respectively, which was consistent with the study of Brønden et al. (1). Further examination of the eye as biopsy and/or operation material (n=27) and the diagnosis of sebaceous tumors in most of them (59.2%) had associated results in terms of tumor type and localization. It has been reported that the study is similar to the general information in terms of the frequent observation of tumors in the mouth region in dogs, with the most common being melanocytic tumors (30-40%), squamous cell cancer (15-25%) and fibrosarcoma (4). In this study, contrary to previously stated, oral melanocytic tumors (42.8%) and odontogenic tumors including epulis (42.8%) come to the fore.

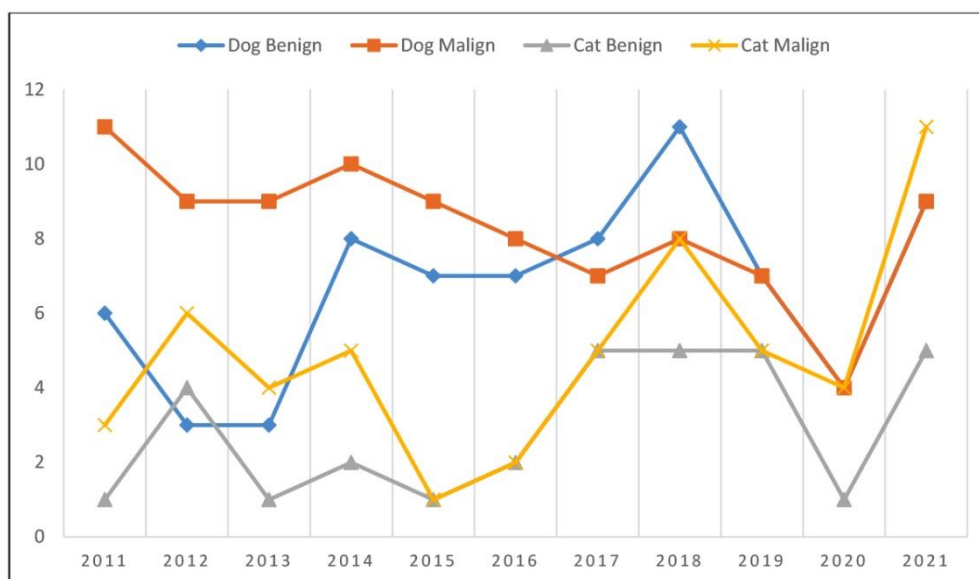
In cats, studies in the head and neck region are quite limited, and the most common epithelial tumors observed in this study and the higher percentage of squamous cell cancer among epithelial tumors are similar to other studies (1, 7).

As a result, epithelial tumors were observed most frequently in dogs. There were papillomas in benign tumors and squamous cell carcinomas in malignant tumors. Considering their localization, epithelial benign and malignant tumors were mostly observed in the eyes, while mesenchymal benign and malignant tumors were encountered in the mouth. Although there was not much difference between the number of mesenchymal tumors, tumors were most frequently encountered in the mouth. Epithelial tumors were also observed most frequently in cats, and squamous cell cancer was the most prominent tumor type. Epithelial tumors were most frequently encountered in the nose and mouth in cats. Although there is not much difference between the number of mesenchymal tumors, malignant and benign mesenchymal tumors were most common in the ear and neck regions, and fibromas, fibrosarcomas, and hemangiosarcomas were the most common.

Of all other tumors in cats, plasmacytoma and melanoma, as mentioned in the tables and texts, were the most striking. Among the other tumors seen in dogs, mostly benign and malignant melanomas were diagnosed.

In the study, while the results and general characteristics of two different species were examined in detail, comparisons between both species were avoided.

When the number of cases observed by year is evaluated, it is noteworthy that there is a decrease in the number of tumors in both dogs and cats in 2020. This was undoubtedly due to the decrease in the total number of materials experienced due to the Covid-19 pandemic. The number of benign and malignant cases by year is as indicated in Figure 2.



**Figure 2.** Distribution of benign and malignant tumors in the head and neck region of cats and dogs by years.



## Acknowledgements

We would like to thank the members of Department of Pathology, Faculty of Veterinary Medicine of Ankara University for their contributions during the diagnosis phase, and the clinics of the faculty hospital and private institutions for the supply of materials.

## Financial Support

This research received no grant from any funding agency/sector.

## Author Contributions

GYT conceived the idea and planned the manuscript for this review article. OBD made the archive researches for the samples dated in between the years 2011-2021 and prepared the tables. GYT took the lead in the literature review and writing the manuscript. SAV and OK have made significant scientific support and also contributed to the interpretation of the results. All authors provided significant contributions by giving feedback and help shape the manuscript.

## Data Availability Statement

The data supporting this study's findings are available from the corresponding author upon reasonable request.

## Ethical Statement

Ethical approval was found unnecessary due to the fact that no experiments were done on animals.

## Conflict of Interest

The authors declared that there is no conflict of interest.

## References

1. Brønden LB, Eriksen T, Kristensen AT (2009): *Oral malignant melanomas and other head and neck neoplasms in Danish dogs-data from the Danish Veterinary Cancer Registry*. Acta Vet Scand, **51**, 1-6.
2. Dorn CR, Priester WA (1976): *Epidemiologic analysis of oral and pharyngeal cancer in dogs, cats, horses, and cattle*. JAVMA, **169**, 1201-1206.
3. Ertürk E, Tanzer F, Bulucu M (1971): *Patolojik anatomi kürsüsünde 1964-70 yılları arasında incelenen köpek ve kedi tümörleri*. Ankara Univ Vet Fak Derg, **18**, 383-386.
4. Goldschmidt MH, Goldschmidt, KH (2016): Epithelial and melanocytic tumors of the skin. 88-141. In: Meuten (Ed), *Tumors in Domestic Animals*. WILEY Blackwell, Iowa.
5. Gorlin RJ, Barron CN, Chaudhry AP, et al (1959): *The oral and pharyngeal tumours of domestic animals: a study of 487 cases*. Am J Vet Res, **20**, 1032-1061.
6. Gülçubuk A, Gürel A (2003): *1995-2000 Yılları arasında İstanbul'da saptanan köpek tümörleri*. İstanbul Üniv Vet Fak Derg, **29**, 83-91.
7. Kutlu T, Yücel G, Ekebaş G, et al (2015): *2000-2010 yılları arasında incelenen kedi ve köpeklerdeki baş bölgesi tümörleri*. Vet Hekim Der Derg, **86**, 34-41.
8. Meuten DJ (2016): *Tumors in domestic animals*. 5<sup>th</sup> Ed. John Wiley & Sons, Iowa.
9. Pamukçu AM, Ertürk E (1962): *Ankara'da köpeklerde görülen tümör çeşitleri*. Ankara Univ Vet Fak Derg, **9**, 1-9.
10. Pinello K, Pires I, Castro AF, et al (2022): *Cross Species Analysis and Comparison of Tumors in Dogs and Cats, by Age, Sex, Topography and Main Morphologies*. Vet Sci, **9**, 167.
11. Tannehill-Gregg SH, Levine AL (2006): *Rosol, T.J. Feline head and neck squamous cell carcinoma: A natural model for the human disease and development of a mouse model*. Vet Comp Oncol, **4**, 84-97.
12. Vural SA, Keleş H, Özsoy ŞY, et al (2007): *Köpek ve kedilerde 1977-2005 yılları arasında saptanan orofaringeal bölge tümörleri: retrospektif çalışma*. Ankara Univ Vet Fak Derg, **54**, 197-203.

## Publisher's Note

All claims expressed in this article are solely those of the authors and do not necessarily represent those of their affiliated organizations, or those of the publisher, the editors and the reviewers. Any product that may be evaluated in this article, or claim that may be made by its manufacturer, is not guaranteed or endorsed by the publisher.