

Management of inflammatory bowel disease and lymphangiectasia in a dog with octreotide and tranexamic acid

Yiğit KAÇAR^{1,a,✉}, Zehra Avcı KÜPELİ^{2,b}, Uygur CANATAN^{3,c}, Özgür ÖZYİĞİT^{2,d}, Nihal Yaşar GÜL SATAR^{3,e}, Ethem Mutlu TEMİZEL^{1,f}

¹Department of Internal Medicine, Faculty of Veterinary Medicine, Bursa Uludağ University, Bursa, Türkiye; ²Department of Pathology, Faculty of Veterinary Medicine, Bursa Uludağ University, Bursa, Türkiye; ³Department of Surgery, Faculty of Veterinary Medicine, Bursa Uludağ University, Bursa, Türkiye

^a0000-0002-8389-4833; ^b0000-0003-1853-4679; ^c0000-0001-9650-0891; ^d0000-0003-0682-8127; ^e0000-0002-3505-3394; ^f0000-0002-4828-4116

ARTICLE INFO

Article History

Received : 10.03.2023

Accepted : 10.01.2024

DOI: 10.33988/auvfd.1263493

Keywords

Dog

Inflammatory bowel disease

Lymphangiectasia

Octreotide

Tranexamic acid

✉Corresponding author

yigitkacar@uludag.edu.tr

How to cite this article: Kaçar Y, Küpeli ZA, Canatan U, Özyiğit Ö, Gül Satar NY, Temizel EM (XXXX): Management of inflammatory bowel disease and lymphangiectasia in a dog with octreotide and tranexamic acid. Ankara Univ Vet Fak Derg, XX (X), 000-000. DOI: 10.33988/auvfd.1263493.

ABSTRACT

In dogs, inflammatory bowel disease (IBD) is a well-defined form of intestinal disease. Most cases are associated with lymphangiectasia. A 2-year-old, American Staffordshire Terrier male dog, presented with progressive diarrhea for more than 3 months. Clinical findings, laboratory findings, ultrasound images of the dog and also, histopathological evaluation of punch biopsy samples from the intestines were compatible with IBD and lymphangiectasia. The treatment of the dog was started with the treatment protocol containing octreotide (10 µg/dog per day, BID, sc.) and tranexamic acid (10 mg/kg, BID, im.) which was used for the first time in dogs with IBD and lymphangiectasia. Fecal consistency and defecation frequency returned to normal on the 15th day, also at the end of the first month of therapy hypoalbuminemia began to normalize, ascites completely disappeared and the thickness of the mucosal layer began to normalize, and the patient began to gain weight. In the controls performed at the end of the second month, it was determined that the patient's clinical signs and all laboratory results improved. To our knowledge, these results suggest that the combination of octreotide and tranexamic acid can effectively and without any side effects be used for the treatment of IBD in dogs for the first time. This case report, it is aimed to present a successful treatment method using octreotide and tranexamic acid in a dog with intestinal lymphangiectasia related to IBD and to raise awareness among veterinarians in patients with similar clinical findings.

Inflammatory Bowel Disease (IBD) is a complex disease that is characterized by cellular infiltration within intestinal layers (1, 2, 5, 11, 23, 28). Lymphocytic, lymphoplasmacytic enteritis, eosinophilic gastroenteritis, and mixed inflammation are the most frequently encountered types of IBD in dogs (1, 5). Malabsorption and chronic protein-losing enteropathy may result from prominent lymphocyte and plasmacyte infiltration in the lamina propria. The most frequently encountered complication is intestinal lymphangiectasia, which is characterized by the dilation of lymph vessels (18). Enlargement of the lacteals results in decreased lymph

absorption in the lamina propria and subsequent loss of protein and other nutrients into the intestinal lumen (28). Diarrhea is the most common symptom in dogs with intestinal lymphangiectasia and IBD but also weight loss, ascites, peripheral edema, vomiting, anorexia, hydrothorax, chylothorax, flatulence, lethargy, borborygmus, hematemesis, melena, and abdominal pain can be seen in these dogs (1, 8, 11, 17).

The diagnosis of IBD and intestinal lymphangiectasia can be made by clinical signs, biochemical examinations, ultrasonography, and histopathologic examination (1, 4, 11, 17, 18, 27). Dogs

with intestinal lymphangiectasia related to IBD usually need long-term treatment and they may have a poor prognosis in many cases (18). Conventional treatment of IBD and intestinal lymphangiectasia in dogs have consisted of resolution of the underlying disease, dietary modification (low-fat diet especially long-chain triglyceride restriction), and pharmacological therapy (immunosuppressive drugs, NSAID, etc.) (1, 5, 11, 18, 23). However, since these drugs, used in the treatment of IBD with lymphangiectasia have limited effectiveness, the search for more effective drugs continues today.

Octreotide is a synthetic somatostatin analogue, and it affects many organ systems, especially the gastrointestinal tract (10, 22). It has been suggested that octreotide promotes the relaxation of intestinal smooth muscles, decreases gastrointestinal motility, and reduces secretory diarrhea (antisecretory effect) by enhanced water and electrolyte absorption, reduces jejunal secretions, and alters ion transport in the gastrointestinal tract (10, 14, 17, 22). Also, it has been stated that octreotide reduces the perception of gastric, colonic, and rectal distension in IBD patients (14). In addition, it is commonly used in controlling lymphatic leakage in humans and a dramatic decrease in lymphatic output can occur (25).

Tranexamic acid is also used in children with IBD. In this disease, increased fibrinolytic activity can increase protein loss from the intestinal area. Tranexamic acid reduces the fibrinolytic activity, so with this property, it may contribute to the treatment of the disease (15, 20).

Here we present a case report of the dog with intestinal lymphangiectasia related to IBD which was

successfully treated with octreotide and tranexamic acid.

Case description: A 2-year-old, 23 kg body weight, male American Staffordshire Terrier was referred due to diarrhea lasting for more than 3 months to Bursa Uludag University Faculty of Veterinary Medicine, Department of Internal Medicine. Anamnesticly the dog was castrated a few months ago, and diarrhea and vomiting were worsening gradually after the operation. It was also reported that the dog has lost about 10 kg weight during this time. It has been noted that abdominal enlargement was revealed in the dog for 1-2 weeks. The dog had a good appetite and was fed commercial dog food (Enjoy[®], adult dog food, Lider Petfood Industry and Trade Ltd. Co, Turkey). It was stated that despite the many therapeutic efforts, could not be recovered including ampicillin sulbactam, enrofloxacin, gentamicin, ranitidine, metoclopramide, and probiotic treatments. In addition, all vaccinations and internal-external parasitic (anthelmintic and parasitic) applications were performed routinely. All physiological parameters were within reference limits (P:88/Bpm, R:36/min, T:38.5/°C, CRT:2 sec., Lymph Nodes: Normal), on the other hand, abdominal palpation revealed fluctuation with tension and moderate abdominal pain (Table 1, Figure 1 and Figure 2). The fecal consistency was scored based on a 5-point scale (1= very hard to 5= watery diarrhea) (16) during the treatment period. According to the owner's description and our clinical examination, fecal scores were described as 5. The dog's stool had a yellowish-colored and oily appearance but didn't contain any undigested food.

Table 1. Pre-treatment (Day 0), during treatment (Day 0-60), and after treatment (Day 180) haemogram results.

Parameter	Day 0	Day 15	Day 30	Day 60	Day180	References (26)
WBC (10 ³ /mm ³)	16.44	31.15	15.10	15.84	8.91	6.0-17.0
Lymphocyte (10 ³ /mm ³)	0.96	0	2.73	2.89	2.28	1.0-4.8
Monocyte (10 ³ /mm ³)	0.02	0	0.46	1.37	0.58	0.1-1.3
Neutrophil (mm ³)	15.13	31.00	11.82	11.38	5.66	3.0-13.5
Eosinophil (10 ³ /mm ³)	0.33	0.16	0.07	0.17	0.30	0.1-1.2
Basophil (mm ³)	0.00	0.00	0.00	0.00	0.10	0.0-0.1
nRBC (10 ⁶ / mm ³)	4.36	2.41	7.45	3.41	3.44	0.0-99.9
RBC (10 ⁶ /mm ³)	7.84	4.40	6.32	7.27	7.97	5.5-8.5
HGB (g/dL)	21.00	11.60	15.00	18.60	18.90	12.0-18.0
HCT (%)	56.10	30.70	44.10	47.80	53.00	37.0-55.0
MCV (fL)	71.60	69.90	69.90	65.80	66.50	60.0-77.0
MCHC g/dL)	37.40	37.70	34.00	38.90	35.60	32.0-36.0
PLT (mm ³)	663.000	482.000	473.000	331.000	353.000	200.0-500.0

WBC: White blood cells; nRBC: Nucleated red blood cells; RBC: Red blood cells; HGB: Hemoglobin; HCT: Hematocrit; MCV: Mean corpuscular volume; MCHC: Mean corpuscular hemoglobin concentration; PLT: Platelet count

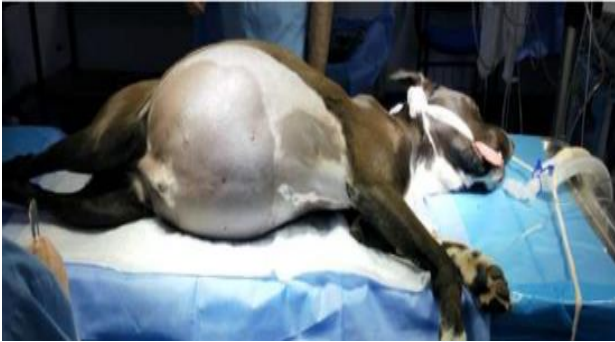

Figure 1. Abdominal distention (dilatation with ascites fluid).



Figure 2. Ascites fluid in the abdomen (10 L).

Diagnostic procedures: The haemogram and serum biochemistry results are presented in Table 1 and Table 2. There were no parasites in the fecal examination and the occult blood test was negative. Also, there was no abnormality in the results of the radiographic, electrocardiographic, and echocardiographic examinations. The anechoic-free fluid (ascites) in the abdomen was observed in the ultrasonographic examination. In the ultrasonographic examination of the intestines, it was found that the total wall thickness increased (0.68 cm), especially the mucosal layer was 0.56 cm. Since it is known that the normal total wall thickness of the duodenum in dogs is 0.53 cm or less (7), it was determined that the mucosal layer thickness was increased in this dog (Figure 3). Also, rivolta test of the abdominal fluid (ascites) that was taken by abdominocentesis was determined as transudate. Also, there were no abnormalities detected on the urinalysis of the dog. On the other hand, the patient's TLI value which was measured by using a commercial assay (Canine TLI-RIA, Siemens Medical Solutions, Malvern, PA) was found to be lower than the references. Based on clinical signs and laboratory

findings, the patient was diagnosed with inflammatory bowel disease and exocrine pancreatic insufficiency.

All treatment protocols applied to the dog are summarized in Table 3. Also, a fat-restricted but protein-rich diet was applied to the dog with the initiation of the first treatment protocol. Despite these first two treatment protocols, the patient's clinical and laboratory findings have not improved, so exploratory laparotomy was performed. In the exploratory laparotomy, approximately 10 liters of free fluid (ascites) was drained from the abdomen (Figure 2). On the inspection, thickening was observed in some areas of the duodenum and jejunum. Punch biopsy samples of approximately 3 mm in size, including all intestinal layers, were taken from this thickened area of the duodenum and jejunum. Also, punch biopsy samples were taken from the pancreas. Biopsy samples were sent to the Department of Pathology for histopathological examination.

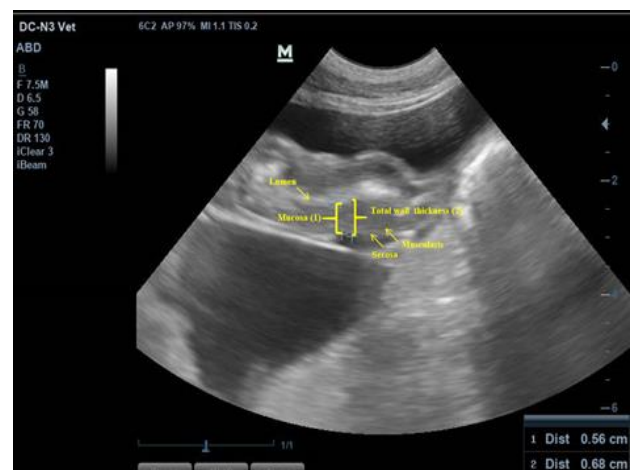

Figure 3. Pre-treatment US appearance of duodenum.

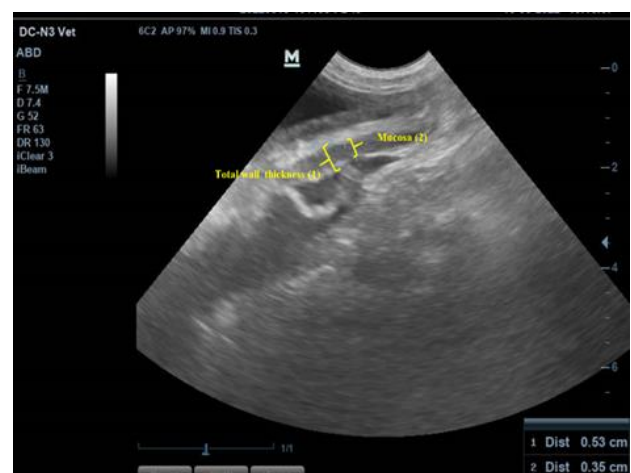

Figure 4. Post-treatment US appearance of duodenum.

Table 2. Pre-treatment (Day 0), during treatment (Day 0-60) and after treatment (Day 180) serum biochemistry results.

Parameter	Day 0	Day 15	Day 30	Day 60	Day 180	References (26)
Total protein (g/dL)	2.60	-	3.7	6.1	6.60	5.1-7.8
Albumin (g/dL)	1.20	1.30	2.3	3.3	3.30	2.6-4.3
Globulin (g/dL)	1.40	-	1.4	2.8	3.30	2.3-4.5
Alb/Glob	0.86	-	1.64	1.17	1.00	0.9-1.9
Alkaline phosphatase (U/L)	57.00	125.00	-	100.5	59.00	10-150
Glucose (mg/dL)	129.00	112.00	-	113.00	101.00	60-125
Total bilirubin (mg/dL)	0.20	0.40	-	0.20	0.20	0.0-0.4
Inorganic phosphorus (mg/dL)	3.20	-	-	3.40	3.80	2.9-5.3
Total cholesterol (mg/dL)	<50.00	-	-	-	254.00	112-328
Gamma-glutamyl-transferase (GGT) (U/L)	<10.00	20.00	-	<10.00	<10.00	0.0-10.0
Alanine-aminotransferase (ALT) (U/L)	127.00	219.00	-	98.00	96.00	5-60
Calcium (mg/dL)	7.20	-	-	9.5	11.60	7.5-11.3
Creatinine (mg/dL)	0.51	-	0.26	0.56	0.80	0.4-1.8
Blood urea nitrogen (mg/dL)	9.80	-	19.60	20.1	15.50	7-27
Ammonia (NH ₃) (mol/L)	-	54.00	-	38.00	-	40-70

Table 3. Treatment protocols which applied to the dog.

Initial treatment protocol	Re-admission treatment protocol	Treatment protocol after definitive diagnosis
fat-restricted but the protein-rich diet	fat-restricted but the protein-rich diet	fat-restricted but the protein-rich diet
sulfasalazine (Salazopyrin®, Pfizer; 20 mg/kg, TID, po.)	sulfasalazine (Salazopyrin®, Pfizer; 20 mg/kg, TID, po.)	sulfasalazine (Salazopyrin®, Pfizer; 40 mg/kg, TID, po.)
methylprednisolone (Prednol®, Mustafa Nevzat; 2 mg/kg, BID, po.)	methylprednisolone (Prednol®, Mustafa Nevzat; 3 mg/kg, BID, po.) cyclosporine (Sandimmun neoral®, Novartis; 5 mg/kg, BID, po.)	methylprednisolone (Prednol®, Mustafa Nevzat; 2 mg/kg, BID, po.) cyclosporine (Sandimmun neoral®, Novartis; 10 mg/kg, BID, po.)
metronidazole (Flagyl®, Sanofi; 20 mg/kg, BID, po.) clarithromycin (Klasid®, İE; 20 mg/kg, BID, po.)	amoxiciline+clavulanic acid (Amoklavin®, Deva; 20 mg/kg, BID, po.)	amoxiciline+clavulanic acid (Amoklavin®, Deva; 20 mg/kg, BID, po.)
famotidine (Famodin®, Sandoz; 1mg/kg, BID, po.)	famotidine (Famodin®, Sandoz; 1mg/kg, BID, po.)	famotidine (Famodin®, Sandoz; 1mg/kg, BID, po.),
pankreatin (Pankreoflat®, Recordati; 3 x1 tablet/day)	pankreatin (Pankreoflat®, Recordati; 3 x1 tablet/day)	probiotic complex (Reflor®, Biocodex; 1x1 kps, po.)
hepatic supplement (Hepatiale forte®, Vetexpert; 1x2 tablet, po.) probiotic complex (SynbioCure®, Yeniçağ; 1 chassis /day)	probiotic complex (Reflor®, Biocodex; 1x1 kps, po.)	antidiarrheal agent (Kaopektin®, Alke; 5 ml BID, po.)
antidiarrheal agent (Kaopektin®, Alke; 5 ml BID, po.)	antidiarrheal agent (Kaopektin®, Alke; 5 ml BID, po.)	octreotide (Sandostatin®, Novartis; 10 µg/dog/ day, BID, sc.) tranexamic acid (Transamine®, TEVA; 10 mg/kg, BID, im.)

After laparotomy and histopathological examination of the samples, the definitive diagnosis was intestinal lymphangiectasia and IBD, and a treatment protocol was re-arranged as in Table 3. At control after 1 month, the frequency of vomiting and defecation was decreased, and clinical and laboratory examinations were repeated. In the examination, it was revealed that the fecal score was 3/5.

In the ultrasonographic evaluation, it was determined that no free fluid in the abdomen, kidney, and liver echogenicity was normal, and the total intestinal wall thickness in the duodenum was 0.53 cm (Figure 4) (mucosal layer 0.35 cm) was thinner than before (0.56 cm). In this control, the dog's weight was found to be 26 kg (it gained about 3 kg). Afterward, the treatment was

continued in the same way for 1 more month and terminated. At the end of the treatment, abdominal distension (ascites) and other clinical problems (vomiting, diarrhea, etc.) were completely resolved, and the dog was 29 kg by gaining 3 more kg. In the controls which were made during and up to 6 months after the treatment protocol, it was determined that the disease did not recur and there was no problem.

In veterinary medicine, mainly prednisone, prednisolone, sulfasalazine, olsalazine, azathioprine, cyclophosphamide, cyclosporine, and metronidazole were used in dogs with IBD up to date (1, 18, 23). Also, in recent years, there have been studies on the use of probiotics, mesenchymal stem cells, fecal microbiota transplantation, and therapeutic helminths in the treatment of IBD (3, 6, 21). In the treatment of IBD, considering the possible lymphangiectasia and clinical consequences in addition to the above-mentioned conventional treatments, additional medical options may play an important role in the success of the treatment.

It has been reported that in patients with IBD, lamina propria inflammatory cell infiltrates may lead to lymphangiectasia by blocking the flow in the mesenteric lymph nodes. It has also been suggested that the increased vascular permeability associated with IBD may contribute to mucosal edema and lymphatic dilatation (12). In this case, marked clinical signs, and histopathological changes were determined to be compatible with IBD and lymphangiectasia (Figure 5 and Figure 6). Therefore, also the correction of lymphangiectasia is important in the treatment of IBD. Octreotide is highly effective in preventing lymphatic leakage (17). Indeed, studies in children (15) and adults (25) with lymphangiectasia have shown that the use of octreotide is effective. It has also been reported that people with chylothorax also prevent chylous fluid accumulation by narrowing the lymphatic vessels (19). In humans, tranexamic acid is also used as part of IBD and lymphangiectasia therapy protocols. Increased fibrinolytic activity may promote intestinal protein loss in humans (15, 20). It has been observed that protein-rich fluid excretion and so hypoproteinemia is prevented resulting in the narrowing of the enlarged lymphatic vessels and reduction of chylous leakage by using octreotide in addition to the conventional treatment. Therefore, tranexamic acid in patients with IBD has been commonly used to prevent intestine protein loss. In this case, the tranexamic acid and octreotide combination improved diarrhea and ascites after 1 month.

There are no known standardized dosage and usage duration of octreotide in dogs (15, 22). It is reported that octreotide (long-acting formulation) was used in a dog with osteosarcoma at a dose of 60 mg/per dog three times 21 days apart (13), but in the treatment of insulinoma, this drug was used at a dose of 2µg/kg (24). This paper used

the octreotide dose at 10 µg/day with clinical success for 2 months. (22).

There are not many reports about the side effects of octreotide in dogs. It is well tolerated in humans and the primary side effect is pain in the local injection site and some gastrointestinal symptoms like anorexia and nausea (10). In dogs, octreotide is a well-tolerated drug except for sterile injection site abscessation (13). In this case, no local or systemic drug-related side effects were observed in the dog during the 2-month treatment protocol. Although it has been reported that long-term use of octreotide may lead to the formation of gallstones and liver damage, no adverse effects on liver functions and gallbladder were observed in the presented case (9). In this case, liver biomarkers (ALT, AST, BUN, ALB) and abdominal ultrasonography were regularly evaluated during the two-month treatment period. All biochemical, hematologic, and ultrasonographic findings in terms of 6 months were within reference limits (Table 1 and Table 2).

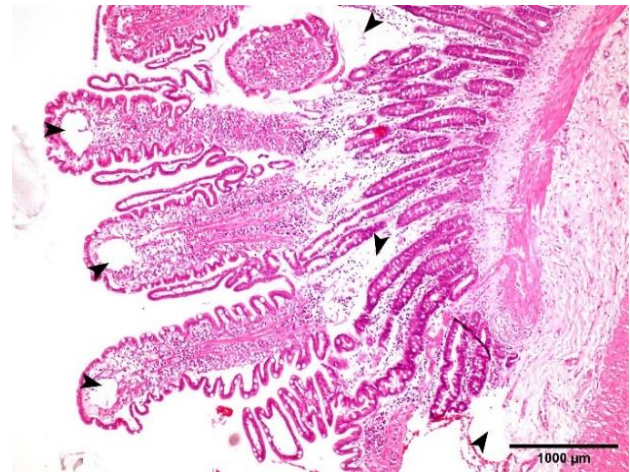


Figure 5. Jejunum-Lymphangiectasia. Lacteal dilatation and oedema in the villi and lamina propria (arrowheads).

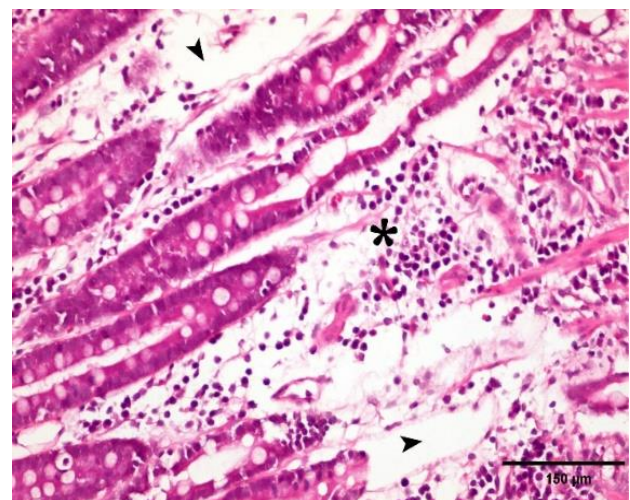


Figure 6. Jejunum-Lymphangiectasia. Inflammatory cell infiltration from a large number of mononuclear series in lamina propria (asterisk). Lacteals are dilated (arrowheads). HEX40.

In the veterinary literature, the effectiveness of octreotide and tranexamic acid in a dog with IBD and lymphangiectasis is demonstrated for the first time. Further clinical research is needed to determine the relationship between octreotide and IBD in dogs.

Financial Support

This research received no grant from any funding agency/sector.

Conflict of Interest

The authors declared that there is no conflict of interest.

Author Contributions

YK and EMT carried out all clinical and laboratory examinations. UC and NYG performed the radiological examinations and exploratory laparotomy operation. ZAK and ÖÖ performed the histopathological evaluations. All authors contributed to the writing of the manuscript.

Data Availability Statement

The data supporting this study's findings are available from the corresponding author upon reasonable request.

Ethical Statement

This study does not present any ethical concerns.

Animal Welfare

The authors confirm that they have adhered to ARRIVE Guidelines to protect animals used for scientific purposes.

References

1. **Albert EJ** (1999): *Inflammatory bowel disease: current perspectives*. Vet Clin North Am Small Anim Pract, **29**, 501-521.
2. **Arslan HH** (2006): *Yangısal Baęırsak Hastalıęı ve Probiyotiklerle Güncel Tedavi Yaklařımı*. Uludağ Univ J Fac Vet Med, **25**, 29-32.
3. **Bilgiç B, Bakay Baysal M,B, Ulgen Saka S, et al** (2020): *Kedi ve Köpeklerin Yangısal Baęırsak Hastalıęında Terapötik Helminter*. Türkiye Klinikleri Veteriner Bilimleri, **11**, 92 - 98.
4. **Craven MD, Washabau RJ** (2019): *Comparative pathophysiology and management of protein-losing enteropathy*. J Vet Intern Med, **33**, 383-402.
5. **Craven M, Simpson JW, Ridyard AE, et al** (2004): *Canine inflammatory bowel disease: retrospective analysis of diagnosis and outcome in 80 cases (1995-2002)*. J Small Anim Pract, **45**, 336-342.
6. **Cristóbal JI, Duque FJ, Usón-Casaús JM, et al** (2021): *Effects of Allogeneic Mesenchymal Stem Cell Transplantation in Dogs with Inflammatory Bowel Disease Treated with and without Corticosteroids*. Animals : an open access journal from MDPI, **11**(7), 2061. <https://doi.org/10.3390/ani11072061>
7. **Denning A** (2011): *Ultrasound examination of the gastrointestinal tract Part 1: Location and normal appearance*. Compan Animal, **16**, 21-28.
8. **Díaz-Regañón D, Sainz Á, Rodríguez-Franco F, et al** (2023): *Assessing the Quality of Life of Dogs with Inflammatory Bowel Disease and Their Owners*. Veterinary Sciences, **10**(7), 405.
9. **Han ZH, He ZM, Chen WH, et al** (2021): *Octreotide-induced acute life-threatening gallstones after vicarious contrast medium excretion: A case report*. World J Clin Cases, **9**, 7484-7489.
10. **Harris AG, O'dorisio TM, Woltering EA, et al** (1995): *Consensus statement: octreotide dose titration in secretory diarrhea*. Diarrh Manag Consensus Development Panel Digest Dis Sci, **40**, 1464-1473.
11. **Jergens AE** (2004): *Clinical assessment of disease activity for canine inflammatory bowel disease*. J Am Anim Hosp Assoc **40**, 437-445.
12. **Jubb KVF, Kennedy PC, Palmer NC** (2016): *Veterinary Medicine. Pathology of domestic animals. Alimentary System. 6th ed.*, Elsevier, Riverport Lane, St. Louis, Missouri, 90-91.
13. **Khanna C, Prehn J, Hayden D, et al** (2002): *A randomized controlled trial of octreotide pamoate long-acting release and carboplatin versus carboplatin alone in dogs with naturally occurring osteosarcoma: evaluation of insulin-like growth factor suppression and chemotherapy*. Clin Cancer Res, **8**, 2406-2412.
14. **Klooker TK, Kuiken SD, Lei A, et al** (2007): *Effect of long-term treatment with octreotide on rectal sensitivity in patients with non-constipated irritable bowel syndrome*. Aliment Pharmacol Ther, **26**, 605-615.
15. **Kwon Y, Kim ES, Choe YH, et al** (2021): *Individual approach for treatment of primary intestinal lymphangiectasia in children: single-center experience and review of the literature*. BMC Pediatr, **21**, 21.
16. **Lin CY, Jha AR, Oba PM, et al** (2022): *Longitudinal fecal microbiome and metabolite data demonstrate rapid shifts and subsequent stabilization after an abrupt dietary change in healthy adult dogs*. Anim Microb, **4**, 46.
17. **Makowska K** (2019): *Changes in The Expression of Somatostatin (SOM) in Nerve Fibers of Gastrointestinal Mucosa in Dogs with Inflammatory Bowel Disease (IBD)*. J Med Case Rep, **5**, 90.
18. **Melzer KJ, Sellon RK** (2002): *Canine intestinal lymphangiectasia*. Compendium On Continuing Education For The Practising Veterinarian-North American Edition, **24**:12, 953-961.
19. **Mincher L, Evans J, Jenner MW, et al** (2005): *The successful treatment of chylous effusions in malignant disease with octreotide*. Clin Oncol, **17**, 118-121.
20. **Moore HB, Moore EE, Chapman MP, et al** (2019): *Does Tranexamic Acid Improve Clot Strength in Severely Injured Patients Who Have Elevated Fibrin Degradation Products and Low Fibrinolytic Activity, Measured by Thrombelastography?*. J Am Coll Surg, **229**, 92-101.
21. **Niina A, Kibe R, Suzuki R, et al** (2021): *Fecal microbiota transplantation as a new treatment for canine inflammatory bowel disease*. Bioscience of microbiota, food and health, **40**(2), 98-104.

22. **Plumb DC** (2011): *Octreotide*. In: Plumb DC, ed. *Plumb's Veterinary Drug Handbook*. 7th ed. Stockholm, WI: John Wiley & Sons; 2620-2624.
23. Rhimi S, Kriaa A, Mariaule V. et al (2022): *The Nexus of Diet, Gut Microbiota and Inflammatory Bowel Diseases in Dogs*. *Metabolites*, 12(12), 1176. <https://doi.org/10.3390/metabo12121176>
24. **Simpson KW, Stepien RL, Elwood CM, et al** (1995): *Evaluation of the long-acting somatostatin analogue octreotide in the management of insulinoma in three dogs*. *J Small Anim Pract*, **36**, 161–165.
25. **Suehiro K, Morikage N, Murakami M, et al** (2012): *Late-onset primary intestinal lymphangiectasia successfully managed with octreotide: a case report*. *Ann Vasc Dis* **5**, 96–99.
26. **Tilley LP, Smith, FWK Jr** (2008): *The 5-Minute Veterinary Consult Canine and Feline*, Blackwell's, 1332-1333.
27. **Trinkley KE, Nahata MC** (2011): *Treatment of irritable bowel syndrome*. *J Clin Pharm Ther*, **36**, 275-282.
28. **Zachary JF** (2017): *Veterinary Medicine. Pathologic basis of veterinary disease. Alimentary system and the peritoneum, omentum, mesentery and peritoneal cavity*. 6th ed., Elsevier, Riverport Lane, St. Louis, Missouri, pp. 336-409.

Publisher's Note

All claims expressed in this article are solely those of the authors and do not necessarily represent those of their affiliated organizations, or those of the publisher, the editors and the reviewers. Any product that may be evaluated in this article, or claim that may be made by its manufacturer, is not guaranteed or endorsed by the publisher.
