

Short Communication / Kısa Bilimsel Çalışma

Systemic toxoplasmosis in a kangaroo (*Macropus* sp.)

Yonca Betil KABAK¹, Tolga GÜVENÇ¹, Oğuz KUL², Ahmet DENİZ³, M.Yavuz GÜLBAHAR¹

¹Ondokuz Mayıs Üniversitesi, Veteriner Fakültesi, Patoloji Anabilim Dalı, Samsun; ²Kırıkkale Üniversitesi, Veteriner Fakültesi, Patoloji Anabilim Dalı, Kırıkkale; ³Etlik Veteriner Kontrol ve Araştırma Enstitüsü, Ankara.

Summary: This paper describes systemic toxoplasmosis in a brush kangaroo died after diagnosed with chronic diarrhoea in a local zoo. Macroscopically, widespread subcutaneous petechial haemorrhages, 100 ml sero-sanguineous fluid in the abdominal cavity, many nodular structures on omentum and fat tissues with dilatation in subserosal vessels of gastric and small intestines were observed. Microscopically, necrotic bronchointerstitial pneumonia in the lungs and multiple areas of necroses with pyogranulomatous inflammation in the myocardium, adrenal glands and tunica muscularis of stomach and small intestines were detected. The pancreas and surrounding abdominal adipose tissues had multifocal coalescing acellular necroses conjoined with pyogranulomatous inflammation. Free and/or intracellularly located *Toxoplasma gondii*-like granular structures showed co-association with necrotic lesions. These granular structures and necrotic areas exhibited strong immunoreactivity to polyclonal anti-*T.gondii* antibodies whereas reaction was negative for *Neospora caninum* and *Leishmania sp.*. Nested-PCR designed to amplify a 97 bp long specific part in B1 gene of *T. gondii* gave positive results. In conclusion, the first case of systemic toxoplasmosis in a kangaroo from a local zoo in Turkey was diagnosed by detailed histochemical, immunoperoxidase technique and PCR.

Key words: Immunoperoxidase, kangaroo, PCR, *Toxoplasma gondii*, toxoplasmosis.

Bir kanguruda (*Macropus* sp.) sistemik toksoplazmozis

Özet: Bu çalışma, yerel hayvanat bahçesinde kronik diyare teşhisinden sonra ölen bir çalı kangurusunda (*Macropus* sp.) sistemik toksoplazmozisi tanımlanmaktadır. Makroskopik olarak, deri altında yaygın peteşiyal kanamalar, karın boşluğunda 100 ml kanlı sıvı, omentum ve yağ dokuda pek çok nodüler yapılar ile mide ve ince bağırsakların subserozal damarlarında dilatasyon gözlemlendi. Mikroskopik olarak, akciğerde nekrotik bronkointerstisyel pnömoni ve miyokardium, adrenal bezler ile mide ve ince bağırsakların tunika muskularisinde pyogranülatöz yangı ve çok sayıda nekrotik alan belirlendi. Pankreas ve çevresindeki abdominal yağ dokuda pyogranülatöz yangı ile birleşmiş multifokal asellüler nekroz vardı. Serbest ve /veya intrasellüler yerleşimli *Toxoplasma gondii* antikorları ile şiddetli immunoreaksiyon gösterirken, *Neospora caninum* ve *Leishmania sp.* için reaksiyon negatifti. *Toxoplasma gondii* B1 geninin 97 bp uzunluğunda spesifik bir bölgesine yapılan nested-PCR ile toksoplazmozisin teşhisi doğrulandı. Sonuç olarak, Türkiye’de local bir hayvanat bahçesindeki kanguruda sistemik toksoplazmozis vakası histopatolojik, immunoperoksidaz teknik ve PCR kullanılarak ilk kez teşhis edildi.

Anahtar sözcükler: İmmunoperoksidaz, kanguru, PCR, *Toxoplasma gondii* toksoplazmozis.

Toxoplasma gondii (*T. gondii*) is a protozoan parasite of wild and domestic felids with an unusually wide range of intermediate host. Toxoplasmosis is common in many warm-blooded animals and human (4,6,13,15,17). It is not only a major cause of congenital disease and abortion in human and domestic animals, but also a life-threatening opportunistic infection for immunologically vulnerable hosts (2,3). This is a widespread protozoon in Turkey, therefore, several experimental studies nearby studies representing pathologic and epidemiologic findings of naturally infected animals are present (10,11,12,14). Wallabies and Australian marsupials are considered among the most susceptible species to

toxoplasmosis (2,5,7,17,18). Their vulnerability to toxoplasmosis is explaining with increased stress factors and immunosuppression due to zoo conditions and/or their possibly infrequent contact with feline species during evolution processes (5,6,18). Toxoplasmosis can cause sudden deaths with the absence of prominent clinical findings in captive and wild Australian marsupials, is not always fatal (1,3,4,7,9,18). Clinical findings can be associated with respiratoric, neurologic and gastrointestinal disorders (9,17,18). In the differential and definitive diagnosis of *T. gondii* infections, serologic (e.g. IFA, Sabin Feldman Dye test) (3,4,7,9), ultrastructural (2,8), immunohistochemical (7,8,9,11,12), molecular examinations

(1) and bioassay studies in experimental animals (14,18) generally take place among the main diagnostic tools.

In the present report, fatal toxoplasmosis in a zoo kangaroo was investigated by detailed macroscopic, histopathologic, immunohistochemical and PCR examinations. According to literature, this study is suggested to be the first example of toxoplasmosis in wallabies in Turkey.

A dead adult female brush kangaroo (*Macropus irma*/ Western brush wallaby) was introduced to Department of Pathology, Faculty of Veterinary Medicine, Ondokuz Mayıs University, Turkey, from a local zoo. In necropsy, samples were taken from brain, heart, lung, liver, spleen, kidney, pancreas, adrenal glands, stomach, small and large intestines, regional lymph nodes, omentum, trachea, oesophagus, tongue and skeletal muscles. All tissue samples were fixed in 10% neutral buffered formalin for 24 hours, embedded in paraffin wax, and sectioned at 5 µm thickness. Prepared sections were stained with hematoxylin&eosin (HE), periodic acid-Schiff (PAS), Ziehl- Neelsen (ZN) and Grocott's methenamine silver (GMS) methods (16). Additional sections were immunostained for *T. gondii*, *Neospora caninum* and *Leishmania* sp. using polyclonal antibodies and standard streptavidin-biotin peroxidase complex method (ABC-P) with a commercial kit (Zymed, USA). The reaction product was visualized by aminoethylcarbazole (AEC) chromogen (Zymed, USA) and counterstained with Gill's haematoxylin. Nested-PCR was performed to confirm *T. gondii* infection using 2 primer sets. In the first step; 194 bp part of B1 gene of *T.gondii* (Accession number; AF179871) was amplified using Toxo1 for: 5'-GGAAGTGCATCCGTTTCATGAG-3' and Toxo2 rev: 5'- TCTTTAAAGCGTTCGTGGTC-3' and in the second step a specific 97 bp part of the *T. gondii* B1 gene was targeted in previously amplified template DNA using Toxo3 for: 5'- TGCATAGGTTGCCAGTCACTG-3' and Toxo4 rev 5'-GGCGACCAATCTGCGAATACACC-3' primers. Parasitic DNA was extracted from formalin fixed paraffin embedded tissues as follows; serial 10 µm paraffin tissue sections were cut and 25 µm tissue was collected in a microcentrifuge tube for each paraffin block. Microtome blade was changed in each new sample to prevent cross contamination. After 5 minutes deparaffinization in xylene, tissues were allocated in alcohol and tissue digestion was performed by incubation in 400 µg proteinase K in 500 µl of 10 mM Tris HCl (pH 7.5). PBS was used as negative control, *T. gondii* RH strain tachyzoites obtained from effluent periton of mouse was used as positive control. Consequently, all usual steps of spin colon-centrifuge DNA isolation method were followed according to commercial DNA isolation kit protocol (Qiagen, FFPE DNA extraction kit, Cat. # 51304).

In macroscopic examination, subcutaneous petechial haemorrhages at the lateral of abdominal and thoracic regions and approximately 100 ml sero-sanguineous fluid were observed in abdominal cavity. There were mesenteric and pancreatic lymph node edema, nodular structures scattered throughout the omentum and petechial haemorrhages on the gastric and intestinal serosa. Cranial lobes of the lungs were consolidated.

Microscopically, severe macrophage and lymphocyte infiltrations were present in the lamina propria and submucosa of the stomach and the small intestines in addition to mononuclear cell infiltrations in the areas adjacent to foci of necroses in some muscle fibers. Inflammation and focal necrotic areas were determined in the adrenal medulla, pancreatic parenchyma, peripancreatic (Fig. 1A) and abdominal fat tissues. Steatitis in fat tissues was characterized by multifocal to coalescing acellular necrosis, pyogranulomatous inflammation and peripherally active chronic fibrosis. Inflammatory cells consisted mostly of macrophages, lymphocytes with a few neutrophil leucocytes. Coagulation necrosis and lymphocyte infiltration in portal triad were also observed. There were necrosis and lymphoid depletion in the germinal centers of lymphoid follicles. Additionally, sinusoidal macrophage infiltrations in mesenteric lymph nodes and spleen were noticed. Severe hyperemia in the lungs, oedema, lymphocyte and macrophage infiltrations in interalveolar septal tissue and necrotic bronchiolitis were observed. A focal calcification area confined by a delicate fibrous connective tissue containing lymphocytes and extra and/ or intracellular *T. gondii* tachyzoites were detected. There were multifocal necroses, focal gliosis and meningitis in the brain. Focal necrosis, interstitial macrophages and lymphocytes infiltration were present in the heart and skeletal muscles. Some necrotic areas were calcified in the heart. Free and/or intracellular tachyzoites of the parasite were readily detected in sections of the small intestine, gut, heart, skeletal muscle, pancreatic lymph node and omentum. Tachyzoites were also detected in the granulomatous inflammation occurred in pancreas and adipose tissue around the mesenterium (Fig. 1B), pancreatic lymph nodes and kidneys. PAS and GMS stains were applied to the tissue sections containing various forms of the parasite and results appeared negative. Acid fast bacteria were not observed at the Ziehl Neelsen staining of the lung section showing necroses and calcifications. Immunoperoxidase tests were positive for *T. gondii* (Fig. 1C) but negative for *N. caninum* and for *Leishmania* sp.. *T. gondii* tissue cyst-like structures, free or intracellular tachyzoites showed red in colour granular and cluster-like *T.gondii* specific immunoreactivities with a varying degree depending on the antigenic density. Molecular confirmation was also established by the observation of *T. gondii* specific DNA

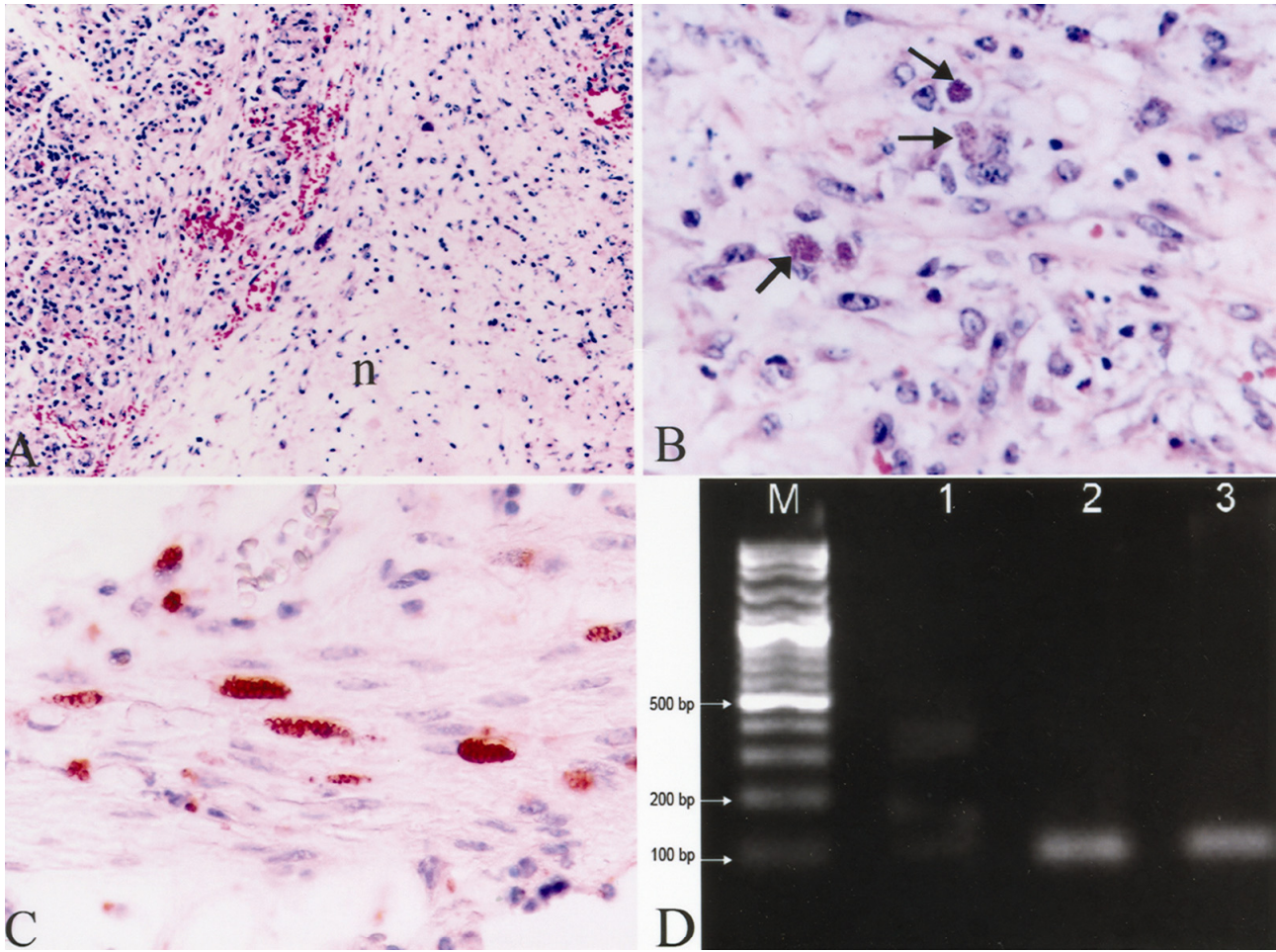


Figure 1. A) Peripancreatitis, (n= necrotic area), Hematoksilen&Eozin x80. B) The phagocytosed *T. gondii* tachyzoites in the necrotic adipose tissue (arrows), Hematoksilen&Eozin x400. C) Immunopositive *T. gondii* tachyzoites in the Tunica muscularis of the stomach, ABC-P x400. D) Agarose gel electrophoresis image of oxidized PCR products, M: DNA marker 100 bp DNA ladder, 1; Negative control, 2; Positive control, 3; Kangaroo pancreas tissue.

Şekil 1. A) Peripankreatitis, (n= nekrotik alan), HE x80. B) Nekrotik yağ dokuda fagosit edilmiş *T. gondii* takizoitleri (oklar), HE x400, C) Midenin Tunika muskularis katında immunopozitif *T. gondii* takizoitleri, ABC-P x400, D) Yükseltgenen PCR ürünlerinin agaroz jel elektroforez görüntüsü. M; DNA marker 100 bp DNA ladder, 1; Negatif kontrol, 2; Pozitif kontrol, 3; Kanguru, pankreas dokusu.

bands (97 bp) in agarose gel after two steps nested-PCR procedure (Fig. 1D).

Toxoplasmosis has been reported in captive wallabies and kangaroos from zoos of various parts of the world (1,2,3,6). Disease generally progresses subclinically in mankind and animals (6,10,13,14,15), while it causes sudden deaths in kangaroos (3,4,9,18). Oocyte shedding subclinically infected stray cats are suspected to be the source of toxoplasmosis in kangaroos (1,4,6).

Toxoplasmosis results with sudden deaths in kangaroos; nevertheless, toxoplasmosis can also show clinical symptoms of diarrhoea, weight gain, tiredness, respiratory and neurologic disorders (2,4,5,6,17). In this case, the zoo veterinarian reported that the kangaroo exhibited only diarrhoea symptom prior to its death.

Lesions are determined in many tissues as a result of the systemic infections occurred by toxoplasmosis in

kangaroo. Concordant with literature, performed necropsy revealed congestion, edema and consolidation in lungs (1,2,3,7,9), lymph node enlargement (3,5,18) and sero-sanguineous fluid accumulation in the abdominal cavity (1,3,17,18). However, it was not noticed, many gross findings related with toxoplasmosis reported in literature such as, splenomegaly (3,5,7,18), sero-sanguineous fluid accumulation in the thoracic cavity and in pericardium (1,2,7,17), focal ulcers and haemorrhagia at the small intestines (1,2,5,17,18), multiple pale foci at myocardium (1, 9, 17,18), enlargement and nutmeg scene at liver (1, 17), haemorrhage at heart, kidneys and lymph nodules (1), malasia at brain (5).

Moreover, the present case showed steatitis in abdominal fat tissues. In kangaroo, steatitis associated with protozoan parasites has been rarely encountered in veterinary literature. Dubey and Hartley (8) reported

steatitis in adipose tissue of a red kangaroo associated with a coccidian-like protozoon. However, they could not identify the parasite by immunohistochemical and ultrastructural examinations. The present case was positive for *T. gondii* antiserum. Moreover, grossly nodular structures were observed in the omentum. In addition to these findings, microscopic detection of multifocal granulomatous inflammation in the lung was firstly diagnosed in this study.

In conclusion, toxoplasmosis in a zoo kangaroo in Turkey is firstly reported by detailed description of its histopathologic, immunohistochemical, and PCR findings.

Acknowledgment

This paper was presented as a poster in IV. National Congress of Veterinary Pathology, 29 October- 02 November 2008, Antalya, Turkey.

References

1. **Basso W, Venturini MC, More G, Quiroga A, Bacigalupe D, Unzaga JM, Larsen A, Laplace R, Vebturini L** (2007): *Toxoplasmosis in captive Bennett's wallabies (Macropus rufogriseus) in Argentina*. Vet Parasitol, **144**, 157-161.
2. **Bermudez R, Failde LD, Losada AP, Nieto JM, Quiroga MI** (2009): *Toxoplasmosis in Bennett's wallabies (Macropus rufogriseus) in Spain*. Vet Parasitol, **160**, 155-158.
3. **Bettiol SS, Obendorf DL, Nowarkowski M, Goldsmid JM** (2000): *Pathology of experimental toxoplasmosis in eastern barred bandicoots in Tasmania*. J Wildlife Dis, **36**, 141-144.
4. **Boorman GA, Kollias GV, Taylor RF** (1977): *An outbreak of toxoplasmosis in wallaroos (Macropus robustus) in a California Zoo*. J Wildlife Dis, **13**, 64-68.
5. **Canfield PJ, Hartley WJ, Dubey JP** (1990): *Lesions of Toxoplasmosis in Australian Marsupials*. J. Comp. Path, **103**, 159-167.
6. **Dubey JP, Beattie CP** (1988): *Toxoplasmosis of Animals and Man*. CRC Press, Florida.
7. **Dubey JP, Ott-Joslin J, Torgerson RW, Topper MJ, Sundberg JP** (1988): *Toxoplasmosis in Black-faced Kangaroos (Macropus fuliginosus melanops)*. Vet Parasitol, **30**, 97-105.
8. **Dubey JP, Hartley WJ** (1992): *Steatitis in a red kangaroo (Macropus rufus) associated with a coccidia-like protozoon*. J Vet Diagn Invest, **4**, 93-96.
9. **Hartley MP** (2006): *Toxoplasma gondii infection in two common wombats (Vombatus ursinus)*. Aust Vet J, **84**, 107-109.
10. **Haziroğlu R, Altın Saat MS, Atasever A, Akın G** (1988): *Kedilerde fatal toksoplazmozis*. AÜ Vet Fak Derg, **35(2-3)**, 330-340.
11. **Haziroğlu R, Gülbahar MY, Altın Taş K** (1994): *Demonstration of toxoplasma gondii antigen in naturally-infected cats using immunoperoxidase technique*. Isr J Vet Med, **49(1)**, 28-30.
12. **Haziroğlu R, Altın Taş K, Atasever A, Gülbahar MY, Kul O, Tunca R** (2003): *Pathological and immunohistochemical studies in rabbits experimentally infected with Toxoplasma gondii*. Turk J Vet Anim Sci, **27**, 285-293.
13. **Haziroğlu R, Milli Ü** (2000): *Veteriner Patoloji*, I Cilt, 1. Baskı, Medipres Yayıncılık, Ankara.
14. **Hökelek M, Kul O, Altın Taş K, Haziroğlu R** (2002): *Deneyisel toxoplazmosiste patolojik bulgular*. T Parazitoloj Derg, **26(1)**, 17-19.
15. **Jubb KVF, Kennedy PC, Palmer N** (2007): *Pathology of domestic animals*. Fifth edition, Vol 2, Elsevier Saunders, China.
16. **Luna LG** (1968): *Manual of Histologic Methods of the Armed Forces Institute of Pathology*. Third ed., McGraw-Hill, New York.
17. **Miller MA, Ehlers K, Dubey JP, Van Steenberg K** (1992): *Outbreak of toxoplasmosis in wallabies on exotic animal farm*. J Vet Diagn Invest, **4**, 480-483.
18. **Reddachff GL, Hartley WJ, Dubey JP, Cooper DW** (1993): *Pathology of experimentally-induced, acute toxoplasmosis in macropods*. Aust Vet J, **70**, 4-6.

Geliş tarihi: 30.06.2009 / Kabul tarihi: 29.09.2010

Address for correspondence:

Yonca Betil Kabak
Ondokuz Mayıs University, Faculty of Veterinary Medicine
Department of Pathology
55139 Kurupelit- SAMSUN, TURKEY.
e-mail: ybkabak@omu.edu.tr