

Short Communication / Kısa Bilimsel Çalışma

**Pleuritis and pneumonia associated with nocardiosis and aspergillosis
in a domestic short haired cat**

Rıfki HAZIROĞLU¹, Mehmet ŞAHAL², Recai TUNCA³, Tolga GUVENC⁴,
SibelYasa DURU², Lale ATASEVEN⁵

¹Department of Pathology, Veterinary Medicine, Ankara University, 06110 Diskapi, Ankara, Turkey; ²Department of Internal Medicine, Veterinary Medicine, Ankara University, 06110 Diskapi, Ankara, Turkey; ³Department of Pathology, Veterinary Medicine, University of Kafkas, 36100 Pasacayırı, Kars, Turkey. ⁴Department of Pathology, Veterinary Medicine, University of 19 Mayıs, 55139 Kurupelit, Samsun, Turkey. ⁵Department of Microbiology, Provincial Control Laboratory, Van, Turkey.

Summary: A severe, pyogranulomatous inflammation of the pleura and pnömonia associated with *Nocardia* spp. and *Aspergillus fumigatus* was described in 9 month-old, domestic short haired male cat to the respect of clinical, microbiological and pathological aspects. Severe abdominal respiration, open-mouthed breathing, weakness, dehydration and fever 39.6 °C were observed clinically. There was yellowish brown fluid in the thoracic cavity. Thick pleura and multiple adhesions were detected at necropsy. Many necrotic and pyogranulomatous lesions were observed histologically.

Key words: Aspergillosis, cat, nocardiosis, pleuritis, pneumonia

Evcil kısa tüylü bir kedide plöritis ve pnömoni ile karakterize nokardiozis ve aspergilozis

Özet: Erkek, kısa tüylü, 9 aylık, evcil bir kedide *Nocardia* spp. ve *Aspergillus fumigatus* tarafından oluşturulan, şiddetli pyogranülomatöz plöritis ve pnömoni olgusu klinik, patolojik ve mikrobiyolojik yönleri ile tanımlandı. Klinik olarak şiddetli abdominal solunum, ağız açık vaziyette nefes alma, güçsüzlük, dehidrasyon ve 39.6 °C ateş gözlemlendi. Nekropside, göğüs boşluğunda sarımtırak kahve renkli sıvı mevcuttu. Plöra kalınlaşmış ve çok sayıda adezyonlar bulunmaktaydı. Histolojik olarak nekrotik, pyogranülomatöz lezyonlar dikkati çekti.

Anahtar sözcükler: Aspergilozis, kedi, nokardiozis, plöritis, pnömoni.

Nocardia is a gram positive, aerobic and branching filamentous bacteria (5). Nocardiosis is acute or chronic infectious disease with granulomatous or suppurative in nature (4-6). *Nocardia asteroides* are most commonly isolated from the nocardiosis cases. *Aspergillus* is a fungal genus, which is widespread in the environment (3). Aspergillosis is either a granulomatous or necrotizing disease in cats, usually affecting lungs and intestines (7,9). These agents are widespread in the environment, although, infections caused by *Nocardia* spp. or *Aspergillus* spp. are more rare in cats (2,3,5,8). Infections caused by individual *Aspergillus* spp. and *Nocardia* spp. have been described by several authors (2,5,7-10), however, there has been no report about dual infection of these agents in cats.

A 9 month-old, domestic short haired male cat, with the complains of respiratoric difficulties and anorexia was brought to the Ankara University, Veterinary Faculty, Internal Medicine Department. The cat was died

after attending the clinic that performed complete clinical examination one week later. The cat was necropsied systemically. Tissue samples were fixed in 10 % neutral buffered formalin, embedded in paraffin wax, sectioned at 5-7 µm. and stained with haematoxylin and eosin. Selected sections were also stained with periodic acid – Schiff (PAS), Brown and Brenn (BB) and Gomori's methenamine silver (GMS).

Severe abdominal respiration, open-mouthed breathing, weakness, dehydration and fever 39.6 °C were observed clinically. The sound of lungs and heart was not clear at the auscultation. There was decreasing in the auscultation area of lungs. The results of hemogram showed that there was an increasing in the white blood cells (44530 n/µl) while erythrocyte (4.23 10⁶µl), hemotocrit (24.0 %) and hemoglobin (5.9 g/dl) levels were detected. The venal blood gases were as follows; blood pH 7.068, base insufficiency -15,8 mmol/l, bicarbonate amount 11,9 mmol/l and pO₂ % 24.3 mmHg.

In radiographic examination, the cranial lobes of the lungs and heart were not clearly seen due to retention of a large amount of an exudate. From the thoracic cavity 50 ml of purulent and red-brownish liquid for bacteriological examination was taken. Oxygen therapy was applied to the cat. Intravenously Ringer lactate, dextrose % 5 and NaCl % 0.9, NaHCO₃ % 1.3 were used to rehydrate and the cat to alleviate the acidosis. Additional antibiotic (lyncomycin-spectinomycin, Lincospectin ® flk.), B-complex (Berovit-B12 ® flk.) and C (Redoxone ® flk.) vitamins were applied. There were no improvements in the patient condition after seven days of treatment. Unfortunately the patient was died and immediately necropsied.

Macroscopically, the thoracic cavity contained approximately 300 ml of purulent yellowish-brown fluid that clotted after the thorax was opened. The pleura was thickened and there were multiple adhesions. The lungs were almost consolidated (Fig 1). The pericardial sac was thickened and adhered to the epicardium.

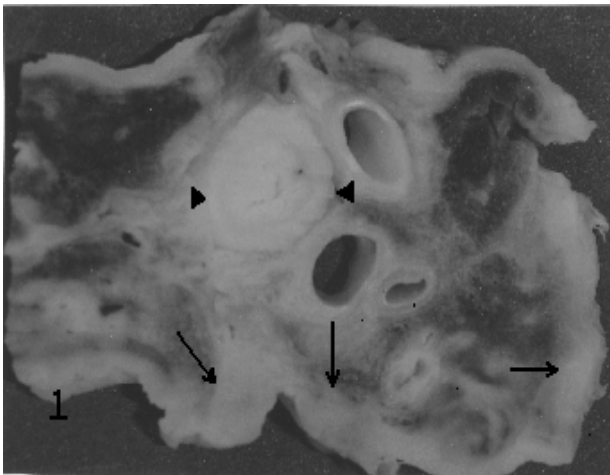


Figure 1: Macroscopic view of the cut surfaces of lungs and oesophagus (arrow heads), showing thickening of the pleura and consolidation of lungs (arrows).

Histopathologically, lesions always involved the serous membranes and extended into the parenchyma; cellular reaction was remarkably similar in each parts of the pleura. Lesions characterized large areas of granulomatous tissue containing several small, irregular and necrotic foci frequently confluent. Necrotic areas were surrounded by fibroblasts, neocapillaries, and mixture of polymorph leukocytes (PML) lymphocytes, plasma cells and macrophages. Numerous interspersed focal and larger accumulations of PML were often surrounded by areas of fibrosis, and many contained organisms colonized in the form of granules (Fig 2 a). When the sections stained with BB, these granules

containing numerous gram-positive, beaded branching bacilli that clearly resemble the *Nocardia* spp. were observed. The filaments were also stained GMS method, however, results of acid-fast staining were negative. Moreover, in the some center of the necrotic areas, septate and branching typical *Aspergillus* spp. hyphae were stained with PAS and GMS. In these areas, the pleural lesions extended into the lungs. The lesions in lungs were appeared to be circumscribed and well demarcated clearly by bands of compressed alveolar tissue and infiltrated with PML. The lesions were comprised with a typical a central zone of acidophilic necrotic debris. A band of tissue not only infiltrated mainly PML, but also plasma and epithelioid cells were detected surrounding this necrotic zone.

Bacteriologically, the specimens from the exudate, pleura, mediastinal lymph nodes and lungs were inoculated on 7% sheep blood agar, Sabouraud dextrose agar (SDA) and Loewenstein Jensen agar. At the end of the incubation period, only *Aspergillus fumigatus* grew on blood agar and SDA (Fig 2 b). There were no *Nocardia* spp. grown in same materials.

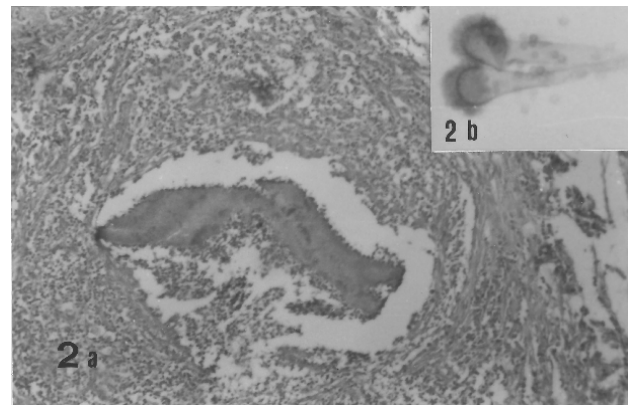


Figure 2: a-A nocardial nodule consisting of masses of organisms, surrounded by polymorphnuclear leucocytes, mononuclear cells and fibroblasts. HE x 120. b- Insert preparations of the SDA, showing head of the conidia of *A. fumigatus*. Native examination X 320.

Pleuritis and pneumonia due to dual infection with *Aspergillus* spp. and *Nocardia* spp. have not been described previously. Both infection caused by these agents are often thought to be a complication of some other debilitating disease (3,5,8). The histologic changes in this cat was similar to previous reports (3,5,8,10).

In nocardiosis, prognosis is usually good if the lesion localized but poor to guarded if is systemic or thoracic involvement (1,8). The nocardial agents are enter to the body via inhalation, food or skin wound (1). They have not been usually isolated from the exudates

(8). In this case, the nocardial agents were probably entered to body via inhalation and/or food, since mark/s of the skin wound were not be able to see on the macroscopical examination. As a result, entering route of nocardial agents in this case was still obscure. No bacterial agents were isolated the exudates taken from thoracic cavity on the clinical examination. However, *Aspergillus fumigatus* was isolated from the necropsy materials, but *Nocardia* spp. was not. On the other hand, nocardial agents were identified using histochemical staining methods. This situation could be explained that broad spectrum antibiotics during one week period.

References

1. **Edwards DF.** (1998): *Actinomycosis and nocardiosis*. In Greene. Infectious diseases of the dog and cat. Saunders, Philadelphia, pp. 308-313.
2. **Fox JG, Murphy JC, Shalev M.** (1978): *Systemic fungal infections in cats*. JAVMA, **173**, 1191-1195.
3. **Hazirođlu R** (2001): *Solunum Sistemi*. In: Veteriner Patoloji, (Hazirođlu, R., and U. H. Milli, Eds.), Medipres Ankara, pp. 106-107.
4. **Lobetti RG, M, Collett G, Leisewitz A.** (1993): *Acute fibrinopurulent pneumonia and haemoptysis associated with Nocardia asteroides in three dogs*. Vet Rec, **133**, 480.
5. **Love DN.** (1988): In: *Manual of Small Animal Infectious Diseases*, (Barlough, J. E. Ed) Churchill, Livingston, New York, pp. 208.
6. **Milli UH, Köküslu C, Berkin S.** (1986): *Bir köpekte nocardial plorizi olgusu*. Ankara Üniv Vet Fak Derg, **33**, 171-178.
7. **Pakes SP, New AE, Benbrook SC.** (1967): *Pulmonary aspergillosis in a cat*. JAVMA, **151**, 950-953.
8. **Petric A.D, Tozon N, Cerne M.** (2001): *Nokardiose bei katze und hund : zwei falstudien*. Der Praktische Tierarzt, **82**, 1022-1026.
9. **Stokes R.** (1973): *Intestinal mycosis in a cat*. Aust Vet J, **49**, 499-500.
10. **Tilgner SL, Anstey SI.** (1996): *Nocardial peritonitis in a cat*. Aust Vet J, **74**, 430-432.

Geliş tarihi: 17.11.2005 / Kabul tarihi: 30.11.2005

Address for correspondence:

Dr.Recai Tunca
Kafkas Üniversitesi
Veteriner Fakültesi
Patoloji Anabilim Dalı
36100 Paşaçayırı, Kars-Turkey